

## COURSE GUIDE

### NSC 218 HUMAN ANATOMY IV

**COURSE UNITS:** 2 Credit units (18 hours of instruction online; 12 hours of Discussion forum online/tutorial; 24 hours of laboratory practical)

**Course Team** (Course Writers) Dr. Adewole O.S. MBBS, PhD, (Associate Professor).  
Dr. Abiodun A. O. MBBS, FWCS, M.Sc. (Senior Lecturer)  
Dr. Ayannuga A. A. MBBS, Ph.D (Senior Lecturer)  
Dr. Adeyemi D.A. PhD (Senior Lecturer)  
Dr. Ojo S. K. MBChB, MSc (Lecturer II); Dr. Arayombo B. E. MBChB, MSc (Lecturer II)  
Department of Anatomy and Cell Biology, College of Health Sciences,  
Obafemi Awolowo University, Ile-Ife, Nigeria  
Course Facilitators:  
Dr O.O. Irinoye and Dr E.O Oladogba (Course Editors)  
Professor Mba Okoronkwo OON (Programme Leader)  
Dr S S Bello MBBS, PhD (Course Reviewer)  
Department of Anatomy, FBMS, College of Health Sciences, Usmanu Danfodiyo University, Sokoto, Nigeria



**NATIONAL OPEN UNIVERSITY OF NIGERIA**

© 2021 by NOUN Press  
National Open University of Nigeria  
Headquarters  
University Village  
Plot 91, Cadastral Zone  
Nnamdi Azikiwe Expressway  
Jabi, Abuja

Lagos Office  
14/16 Ahmadu Bello Way  
Victoria Island, Lagos  
e-mail: [centralinfo@nou.edu.ng](mailto:centralinfo@nou.edu.ng)  
URL: [www.nou.edu.ng](http://www.nou.edu.ng)

All rights reserved. No part of this book may be reproduced, in any form or by any means, without exclusive permission in writing from the publisher.

Published by:

Printed by NOUN Press [np@nou.edu.ng](mailto:np@nou.edu.ng)

ISBN:

| <b>CONTENTS</b>                                      | <b>PAGE</b> |
|--|-------------|
| General Introduction .....                           | iv          |
| Course Aims .....                                    | iv          |
| Course Objectives.....                               | iv          |
| Working through the Course .....                     | v           |
| Course Materials.....                                | vi          |
| Study Units .....                                    | vi          |
| Reference Textbooks.....                             | vi          |
| Equipment and Software Needed to Access Course ..... | vii         |
| Number and Places of Meeting.....                    | vii         |
| Discussion Forum.....                                | vii         |
| Course Evaluation.....                               | vii         |
| Grading Criteria.....                                | vii         |
| Grading Scale .....                                  | vii         |
| Schedule of Assignments with Dates.....              | viii        |
| Course Overview.....                                 | viii        |
| How to get the most from this Course.....            | viii        |

## INTRODUCTION

Welcome to the second semester course in Human Anatomy, NSC 218 – Human Anatomy IV. This is a second semester course and a continuation of Human Anatomy I (NSC 215) and Human Anatomy II (NSC 217) where you have increased/improved your knowledge about some, body structures and their organisations. You also covered the protective covering of all the body organs as well as the supporting systems. This second part will cover other internal organs that are important to maintenance of life. As indicated in NSC 215, caring always require sound understanding of the normal structure of the body organs as to know what could be wrong and how such manifest. Basic assessments done before planning general and nursing care usually consider the various organs that function within systems and as interrelated systems. You will be required to be able to describe the integumentary system that maintain, integrate and control body functions. The anatomy of other sense organs such as eye, ear, tongue and olfactory organ shall be covered. The gross anatomy of the brain and spinal cord shall be covered. Peripheral and autonomic nervous system, and discuss the clinical correlates of the body parts. You will enjoy drawing and labelling, as well as seeing some of these organs in real life. You will also see the variations in normal and diseased organs as you are encouraged to participate in all laboratory assignments.

## COURSE OVERVIEW

### Human Anatomy (IV)

Human Anatomy (IV) is the fourth of the courses that covers the major organs that are responsible for life. In this course, we are going to study the integumentary system, the special senses, and the nervous system. These are the regulatory systems. The structures and locations of the various organs that make each of the systems will be studied.

## COURSE OBJECTIVE

**At the completion of this course, you should be able to:**

- Discuss the anatomy and functions of the skin and special senses
- Describe the various disorders of the special senses
- Discuss the formation of the brain and the spinal cord from the most primitive neural tube.
- Discuss the anatomy of the central nervous system.
- Differentiate between structural and functional divisions of the nervous system.
- Discuss the peripheral and autonomic nervous systems

## **COURSE IMPLEMENTATION**

### **DOING THE COURSE**

The course will be delivered adopting the blended learning mode, 70% of online but interactive sessions and 30% of face-to-face during laboratory sessions. You are expected to register for this course online before you can have access to all the materials and have access to the class sessions online. You will have hard and soft copies of course materials, you will also have online interactive sessions, face-to-face sessions with instructors during practical sessions in the laboratory. The interactive online activities will be available to you on the course link on the Website of NOUN. There are activities and assignments online for every unit every week. It is important that you visit the course sites weekly and do all assignments to meet deadlines and to contribute to the topical issues that would be raised for everyone's contribution.

You will be expected to read every module along with all assigned readings to prepare you to have meaningful contributions to all sessions and to complete all activities. It is important that you attempt all the Self-Assessment Questions (SAQ) at the end of every unit to help your understanding of the contents and to help you prepare for the in-course tests and the final examination. You will also be expected to keep a portfolio where you keep all your completed assignments.

### **COURSE REQUIREMENTS AND EXPECTATIONS OF YOU**

Attendance of 95% of all interactive sessions, submission of all assignments to meet deadlines; participation in all CMA, attendance of all laboratory sessions with evidence as provided in the log book, submission of reports from all laboratory practical sessions and attendance of the final course examination. You are also expected to:

1. Be versatile in basic computer skills
2. Participate in all laboratory practical up to 90% of the time
3. Submit personal reports from laboratory practical sessions on schedule
4. Log in to the class online discussion board at least once a week and contribute to ongoing discussions.
5. Contribute actively to group seminar presentations.

## **EQUIPMENT AND SOFTWARE NEEDED TO ACCESS COURSE**

You will be expected to have the following tools:

1. A computer (laptop or desktop or a tablet)
2. Internet access, preferably broadband rather than dial-up access
3. MS Office software – Word PROCESSOR, Powerpoint, Spreadsheet
4. Browser – Preferably Internet Explorer, Moxilla Firefox
5. Adobe Acrobat Reader

## **NUMBER AND PLACES OF MEETING (ONLINE, FACE-TOFACE, LABORATORY PRACTICALS)**

The details of these will be provided to you at the time of commencement of this course

## **DISCUSSION FORUM**

There will be an online discussion forum and topics for discussion will be available for your contributions. It is mandatory that you participate in every discussion every week. Your participation link you, your face, your ideas and views to that of every member of the class and earns you some mark.

## **COURSE EVALUATION**

There are two forms of evaluation of the progress you are making in this course. The first are the series of activities, assignments and end of unit, computer or tutor marked assignments, and laboratory practical sessions and report that constitute the continuous assessment that all carry 30% of the total mark. The second is a written examination with multiple choice, short answers and essay questions that take 70% of the total mark that you will do on completion of the course.

Students evaluation: The students will be assessed and evaluated based on the following criteria

- **IN-COURSE EXAMINATION:**

In line with the university's regulation, in-course examination will come up in the middle of the semester. These would come in form of

Computer Marked Assignment. This will be in addition to 1 compulsory Tutor Marked Assignment (TMA's) and three Computer marked Assignment that comes after every module

- **LABORATORY PRACTICAL:**

Attendance, record of participation and other assignments will be graded and added to the other scores form other forms of examinations.

- **FINAL EXAMINATION:**

The final written examination will come up at the end of the semester comprising essay and objective questions covering all the contents covered in the course. The final examination will amount to 60% of the total grade for the course.

## **LEARNER-FACILITATOR EVALUATION OF THE COURSE**

This will be done through group review, written assessment of learning (theory and laboratory practical) by you and the facilitators.

## **GRADING CRITERIA**

Grades will be based on the following Percentages

|                                     |     |   |     |
|-------------------------------------|-----|---|-----|
| Tutor Marked Individual Assignments | 10% | } | 30% |
| Computer marked Assignment          | 10% |   |     |
| Group assignment                    | 5%  |   |     |
| Discussion Topic participation      | 5%  |   |     |
| Laboratory practical                |     |   | 10% |
| End of Course examination           |     |   | 70% |

## **GRADING SCALE**

A = 70-100

B = 60 - 69

C= 50 - 59

F = < 49

## **SCHEDULE OF ASSIGNMENTS WITH DATES**

To be provided for each module by the facilitator in addition to the ones already spelt out in the course materials.

## **SPECIFIC READING ASSIGNMENTS**

To be provided by each module

## **REFERENCE/FURTHER READING**

Hutchinson, M., Mallat, J., Marieb, E.N., Wilhelm P.B. (2007). A Brief Atlas of the Human Body. Sna Franscisco: Pearson Education Inc.

Katherine M. A. Rogers and William N. Scott (2011) Nurses! Test Yourself in Anatomy and Physiology

Kathryn A. Booth, Terri. D. Wyman (2008) Anatomy, Physiology, and Pathophysiology for Allied Health

Keith L Moore, Persuade T.V.N (2018), The Developing Human Clinically Oriented Embryology 11th Edition Lippincott Williams & Wilkins

Kent M. Van De Graff, R.Ward Rhees, Sidney Palmer (2010) Schaum's Outline of human Anatomy and Physiology 3rd edition.

Philip Tate (2012) Seeley's Principles of Anatomy & Physiology 2nd ed.

Sadler T.W (2012), Langman's Medical Embryology 12th edition.

Seeley's Principles of Anatomy & Physiology, Second edition Published by McGraw-Hill, a business unit of The McGraw-Hill Companies, Inc., 1221 Avenue of the Americas, New York, NY 10020. Copyright c 2012- Chapter 17&18





**MAIN  
COURSE**

| <b>CONTENTS</b> |   | <b>PAGE</b> |
|-----------------|---|-------------|
| <b>Module 1</b> | <b>The Special Senses.....</b>                          | <b>1</b>    |
| Unit 1          | Integumentary System.....                               | 1           |
| Unit 2          | The Tongue and the Sense of Taste.....                  | 12          |
| Unit 3          | The Nose and the Sense of Smell.....                    | 20          |
| Unit 4          | The Ear and the Sense of Hearing.....                   | 25          |
| Unit 5          | The Eyes and the Sense of Vision.....                   | 39          |
| <b>Module 2</b> | <b>The Nervous System.....</b>                          | <b>58</b>   |
| Unit 1          | Embryology of the central nervous system.....           | 58          |
| Unit 2          | Spinal cord.....  | 75          |
| Unit 3          | Brain stem.....   | 83          |
| Unit 4          | Diencephalon and Basal ganglia.....                     | 91          |
| Unit 5          | Cerebral hemisphere.....                                | 98          |
| Unit 6          | Ventricles and cerebrospinal fluid.....                 | 108         |
| Unit 7          | Blood supply of central nervous system...               | 116         |
| <b>MODULE 3</b> | <b>The Peripheral and Autonomic Nervous System.....</b> | <b>125</b>  |
| Unit 1          | Cranial nerves.....                                     | 125         |
| Unit 2          | Spinal nerves.....                                      | 133         |
| Unit 3          | Autonomic nervous system.....                           | 145         |

## **MODULE 1 THE SPECIAL SENSES**

### **UNIT 1 INTEGUMENTARY SYSTEM**

#### **CONTENTS**

- 1.0 Introduction
- 2.0 Objectives
- 3.0 Main Content
  - 3.1 Functions of the integumentary system
  - 3.2 Skin
  - 3.3 Nails
  - 3.4 Hair
  - 3.5 Clinical correlates
- 4.0 Conclusion
- 5.0 Summary
- 6.0 Tutor Marked Assignments
- 7.0 References and other resources

#### **1.0 INTRODUCTION**

The integumentary system is familiar to most people because it covers the outside the appearance of the system It is composed of a complex set of organs that includes the skin and its derivatives (sweat and oil glands, hairs, and nails).

Skin without blemishes is considered attractive, whereas acne is a source of embarrassment for many people. The development of wrinkles and the graying or loss of hair are signs of aging that some people find unattractive. Because of these feelings, much time, effort, and money are spent on changing the appearance of the integumentary system. For example, people apply lotion to their skin, color their hair, and trim their nails. They also try to prevent sweating with antiperspirants and body odor with washing, deodorants, and perfumes.

#### **2.0 OBJECTIVES**

At the end of this unit, you should be able to:

- Describe the components and functions of the integumentary system.
- Explain the role of skin in regulating body temperature.
- Describe the layers of skin and the characteristics of each layer.
- Explain the factors that affect skin colour.
- Outline the disorders associated with the integumentary system.

### 3.0 MAIN CONTENT

#### 3.1 Functions of integumentary System

The appearance of the integumentary system can indicate physiological imbalances in the body. Some disorders, such as acne or warts, affect just the integumentary system. Disorders of other parts of the body can be reflected there, and thus the integumentary system is useful for diagnosis. For example, reduced blood flow through the skin during a heart attack can cause a pale appearance, whereas increased blood flow as a result of fever can cause a flushed appearance. Also, the rashes of some diseases are very characteristic, such as the rashes of measles,

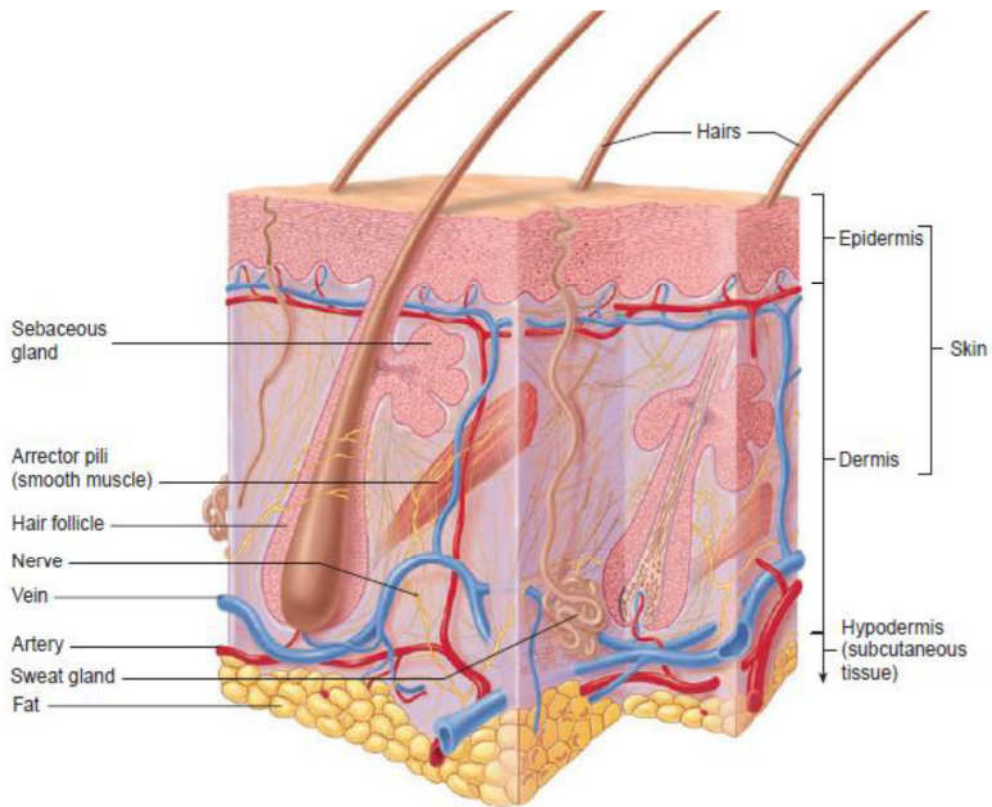
##### Major functions:

1. **Protection:** The skin protects against abrasion and ultraviolet light. It also prevents the entry of microorganisms and prevents dehydration by reducing water loss from the body.
2. **Sensation:** The integumentary system has sensory receptors that can detect heat, cold, touch, pressure, and pain.
3. **Temperature regulation:** Body temperature is regulated through the control of blood flow through the skin and the activity of sweat glands.
4. **Vitamin D production:** When exposed to ultraviolet light, the skin produces a molecule that can be transformed into vitamin D.
5. **Excretion:** Small amounts of waste products are lost through the skin and in gland secretions.

#### 3.2 Skin

The skin is made up of two major tissue layers. The epidermis is the most superficial layer of the skin; it consists of epithelial tissue. The epidermis resists abrasion on the skin's surface and reduces water loss through the skin. The epidermis rests on the dermis, which is a layer of connective tissue. The dermis is responsible for most of the structural strength of the skin. The strength of the dermis is seen in leather, which is produced from the hide (skin) of an animal. The epidermis is removed, and the dermis is preserved by tanning.

The skin rests on the hypodermis which is a layer of loose connective tissue. The hypodermis is not part of the skin or the integumentary system, but it does connect the skin to underlying muscle or bone.



## THE SKIN

| Part               | Structure  | Function   |
|--------------------|--|--|
| <b>Epidermis</b>   | Superficial part of skin; stratified squamous epithelium; composed of four or five strata  | Barrier that prevents water loss and the entry of chemicals and microorganisms; protects against abrasion and ultraviolet light; produces vitamin D; gives rise to hair, nails, and glands |
| Stratum corneum    | Most superficial strata of the epidermis; 25 or more layers of dead squamous cells   | Provision of structural strength by keratin within cells; prevention of water loss by lipids surrounding cells; sloughing off of most superficial cells resists abrasion                   |
| Stratum lucidum    | Three to five layers of dead cells; appears transparent; present in thick skin, absent in most thin skin                               | Dispersion of keratohyalin around keratin fibers   |
| Stratum granulosum | Two to five layers of flattened, diamond-shaped cells  | Production of keratohyalin granules; lamellar bodies release lipids from cells; cells die  |
| Stratum spinosum   | A total of 8–10 layers of many-sided cells   | Production of keratin fibers; formation of lamellar bodies   |
| Stratum basale     | Deepest strata of the epidermis; single layer of cuboidal or columnar cells; basement membrane of the epidermis attaches to the dermis | Production of cells of the most superficial strata; melanocytes produce and contribute melanin, which protects against ultraviolet light   |
| <b>Dermis</b>      | Deep part of skin; connective tissue composed of two layers  | Responsible for the structural strength and flexibility of the skin; the epidermis exchanges gases, nutrients, and waste products with blood vessels in the dermis                         |
| Papillary layer    | Papillae project toward the epidermis; loose connective tissue   | Brings blood vessels close to the epidermis; dermal papillae form fingerprints and footprints  |
| Reticular layer    | Mat of collagen and elastin fibers; dense irregular connective tissue  | Main fibrous layer of the dermis; strong in many directions; forms cleavage lines  |
| <b>Hypodermis</b>  | Not part of the skin; loose connective tissue with abundant fat deposits   | Attaches the dermis to underlying structures; fat tissue provides energy storage, insulation, and padding; blood vessels and nerves from the hypodermis supply the dermis                  |

## COMPARISON OF THE SKIN (EPIDERMIS & DERMIS) AND HYPODERMIS

### Dermis

It is composed of strong and flexible connective tissue. Its cells are typical of those found in any connective tissue proper:

- i. Fibroblasts: cells that form the fibers of connective tissue
- ii. Macrophages: protective cell capable of phagocytosis
- iii. Mast cells: immune cell that initiates inflammation
- iv. White blood cells: protection

Its semifluid matrix is heavily embedded with:

- Collagen: strong, fibrous (threadlike) insoluble protein
- Elastin: extracellular connective tissue protein
- Reticular fibers: supporting framework tissue

The dermis binds the entire body together like a body stocking. It is your hide and corresponds exactly to animal hides used to make leather products. It is richly supplied with nerve fibers, blood vessels, and lymphatic vessels. Major portions of hair follicles, as well as oil and sweat glands, are derived from epidermal tissue but reside in the dermis

### The layers of dermis

1. **The thin, superficial papillary layer:** highly vascularized areolar connective tissue containing a woven mat of collagen and elastin fibers. Its superior surface is thrown into peglike projections called dermal papillae (papill=nipple) that indent the overlying epidermis. Many contain: Capillary loops, meissner's corpuscles: touch receptors and pain receptors.

On the palms of the hands and soles of the feet, these papillae lie atop larger mounds called dermal ridges, which in turn cause the overlying epidermis to form epidermal ridges that increase friction and enhance the gripping ability of the fingers and feet. Epidermal ridge patterns are genetically determined and unique to each of us. Because sweat pores open along their crest, our fingerprints leave identifying films of sweat called fingerprints on almost anything they touch. There are three types of skin markings: Finger prints, Cleavage lines, Flexure lines

2. **The reticular layer:** It is deeper and account for 80% of the thickness of the dermis. Extracellular matrix contains thick bundles of interlacing fibers that run in various planes, most run

parallel to the skin surface, less dense regions, between these bundles form cleavage, or tension lines. Collagen fibers give skin strength and resiliency, binds water, helping keep the skin hydrated while elastin fibers provide the stretch-recoil properties of skin.

**Skin Colour:** This is determined by three pigments: Melanin, Hemoglobin and carotene

Melanin- Only pigment made in the skin, it is a polymer of tyrosine which is an amino acid, ranges in color from yellow to reddish-brown to black. Synthesis depends on an enzyme in melanocytes called tyrosinase. It passes from melanocytes to the basal keratinocytes.

Melanocytes are stimulated by sunlight which causes substantial melanin buildup, which helps protect the DNA of viable skin cells from UV radiation by absorbing the light and dissipating the energy as heat.

Carotene: Yellow to orange pigment found in certain plant products such as carrots. It tends to accumulate in the stratum corneum and in the tissue of the hypodermis, it is the color most obvious in the palms and soles, where the stratum corneum is thickest (example: the skin of the heel).

## **Epidermis**

Derivatives of the epidermis include the Sweat glands, Sebaceous glands, Nails, Hair, Hair Follicles

**Sweat (Sudoriferous) glands:** Distributed over the entire skin surface except the nipples and parts of the external genitalia. Two types of sweat glands:

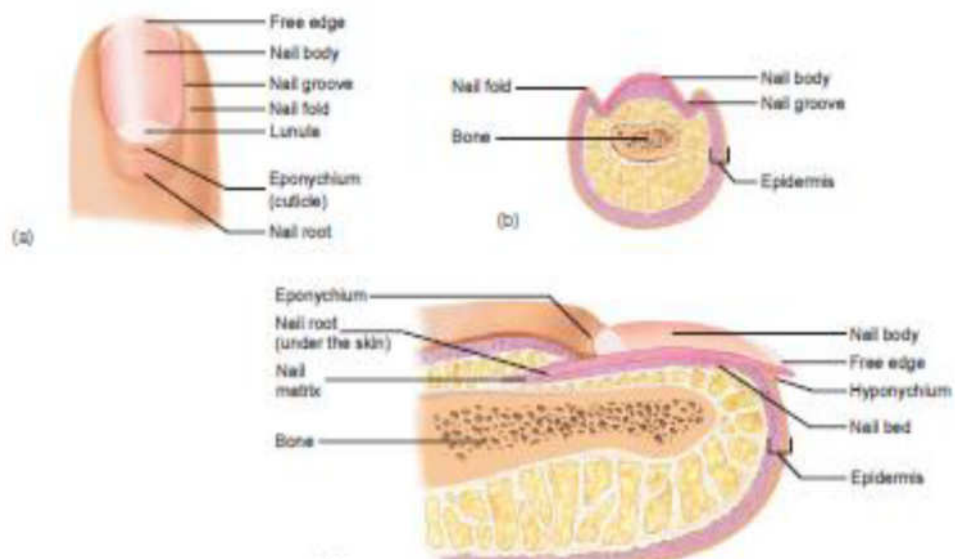
- 1 Eccrine
- 2 Apocrine

**Eccrine:** sweat glands, or merocrine sweat glands, produce true sweat, they are the most numerous of the sweat glands, and are particularly abundant on the palms of the hands, soles of the feet, and forehead. Secretory part lies coiled in the dermis: The duct extends to open in a funnel-shaped pore at the skin surface. Secretion commonly called sweat is a hypotonic filtrate (lower osmotic pressure than a reference) of the blood that passes through the secretory cells of the sweat glands and is released by exocytosis. It contains 99% water, with some salts (mostly sodium chloride), Vitamin C, Antibodies, Dermicidin (microbe-killing peptide and traces of metabolic waste (urea, uric acid, ammonia)

**Apocrine:** It is largely confined to the axillary and anogenital areas, Larger than eccrine glands. Ducts empty into hair follicles. Secretion contains the same basic components as true sweat, plus fatty substances and proteins. Odorless BUT, when its organic molecules are decomposed by bacteria on the skin, it takes on a musky and generally unpleasant odor (BODY ODOR).

### 3.3 Nails

The distal ends of primate digits have nails, whereas most other mammals have claws or hooves. Nails protect the ends of the digits, aid in manipulation and grasping of small objects, and are used for scratching. A nail consists of the proximal nail root and the distal nail body. The nail root is covered by skin, and the nail body is the visible portion of the nail. The lateral and proximal edges of the nail are covered by skin called the nail fold, and the edges are held in place by the nail groove.



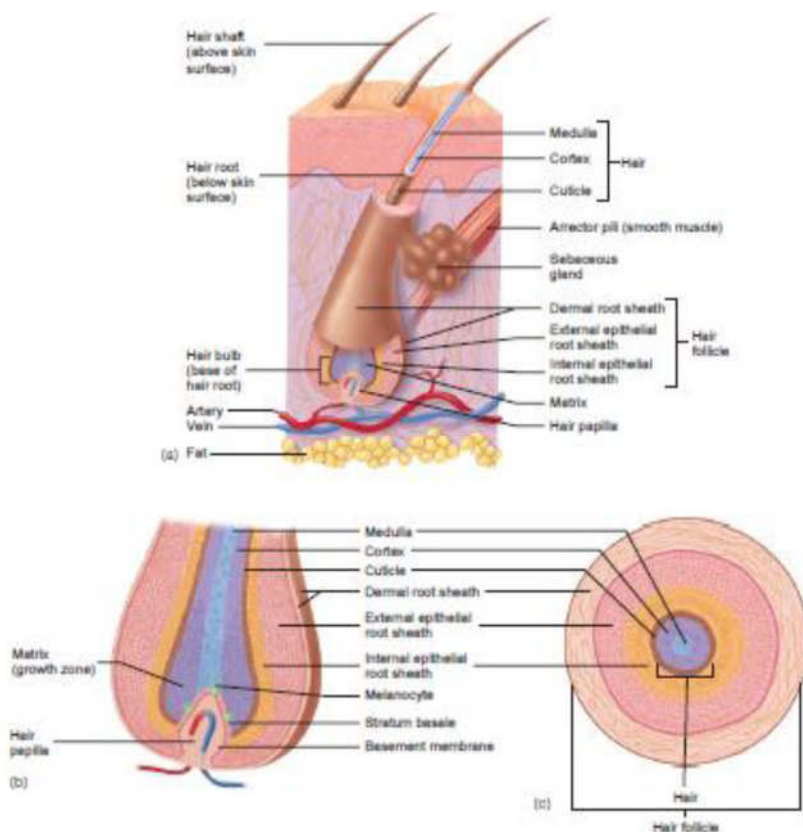
The stratum corneum of the nail fold grows onto the nail body as the eponychium, or cuticle. Beneath the free edge of the nail body is the hyponychium, a thickened region of the stratum corneum. The nail root extends distally from the nail matrix. The nail also attaches to the underlying nail bed, which is located between the nail matrix and the hyponychium. The nail matrix and bed are epithelial tissue, with a stratum basale that gives rise to the cells that form the nail. The nail matrix is thicker than the nail bed and produces nearly all of the nail. The nail bed is visible through the clear nail and appears pink because of blood vessels in the dermis.

A small part of the nail matrix, the lunula, is seen through the nail body as a whitish, crescent-shaped area at the base of the nail. The lunula, seen best on the thumb, appears white because the blood vessels cannot be seen through the thicker nail matrix. The nail contains a hard keratin, which makes the nail hard. As the nail is formed in the nail matrix and bed, it slides over the nail bed toward the distal end of the digit. Nails grow at an average rate of 0.5–1.2 mm per day, and fingernails grow more rapidly than toenails. Unlike hair, they grow continuously throughout life and do not have a resting phase.

### 3.4 Hair

The presence of hair is one of the characteristics common to all mammals; if the hair is dense and covers most of the body surface, it is called fur. In humans, hair is found everywhere on the skin except the palms, the soles, the lips, the nipples, parts of the external genitalia, and the distal segments of the fingers and toes.

By the fifth or sixth month of fetal development, delicate, unpigmented hair called lanugo has developed and covered the fetus. Near the time of birth, terminal hairs, which are long, coarse, and pigmented, replace the lanugo of the scalp, eyelids, and eyebrows. Vellus hairs, which are short, fine, and usually unpigmented, replace the lanugo on the rest of the body.





## The hair follicle

At puberty, terminal hair, especially in the pubic and axillary regions, replaces much of the vellus hair. The hair of the chest, legs, and arms is approximately 90% terminal hair in males, compared with approximately 35% in females. In males, terminal hairs replace the vellus hairs of the face to form the beard. The beard, pubic, and axillary hair are signs of sexual maturity. In addition, pubic and axillary hair may function as wicks for dispersing odors produced by secretions from specialized glands in the pubic and axillary regions. It also has been suggested that pubic hair protects against abrasion during intercourse and axillary hair reduces friction when the arms move.

### 3.5 Clinical correlates

- i. Cleavage lines in the reticular layer of the dermis are important to a surgeon because incision made parallel to these lines, the skin gapes less and heals more readily than when the incision is made across cleavage lines.
- ii. **Folliculitis**, which is a disorder specific to hair, is an inflammation of hair follicles. This disorder usually results from shaving or excess rubbing of skin areas. It may also be caused by bacteria and fungi. Follicles become red and itchy and often look like pimples. Treatments include regular cleansing of skin, topical antibiotics, and use of electric razors instead of razor blades.
- iii. Acne is an active inflammation of the sebaceous glands accompanied by “pimples” (pustules or cysts) on the skin. Usually caused by bacterial infection, particularly by staphylococcus.
- iv. Seborrhea: cradle cap in infants, caused by overactive sebaceous glands. Raised lesions that gradually become yellow to brown and begin to slough off oily scales
- v. A **burn** is injury to a tissue caused by heat, cold, friction, chemicals, electricity, or radiation. Burns are classified according to the extent of surface area involved and the depth of the burn. For an adult, the surface area that is burned can be conveniently estimated by “the rule of nines,” in which the body is divided into areas that are approximately 9%.
- vi. Scabies is a very contagious skin condition. Scabies is caused by mites that burrow beneath skin. Sometimes the burrows of the

mites, which look like red pencil marks, can be seen. Redness and severe itching are usually the only symptoms of scabies. Most cases are easily treated with prescription medications. Because scabies is contagious, it is wise to treat an entire family if one member is infected.

### **Self-Assessment Exercises**

At the histology laboratory, examine slides of the hair, skin and nail and identify the parts of each of these components. Record your findings in the logbook.

- Describe the components and functions of the integumentary system.
- Explain the role of skin in regulating body temperature.
- Describe the layers of skin and the characteristics of each layer.

## **4.0 CONCLUSION**

The integumentary system is familiar to most people because it covers the outside the appearance of the system It is composed of a complex set of organs that includes the skin and its derivatives (sweat and oil glands, hairs, and nails).

## **5.0 SUMMARY**

In this unit, you have learnt that:

- i. The components of the integumentary system includes the skin, the nails, glands and hairs.
- ii. The integumentary system protects us from the external environment. Other functions include sensation, temperature regulation, vitamin D production, and excretion of small amounts of waste products.
- iii. The epidermis is stratified squamous epithelium divided into five strata.
- iv. Melanocytes produce melanin inside melanosomes and then transfer the melanin to keratinocytes. The size and distribution of melanosomes determine skin color. Melanin production is determined genetically but can be influenced by ultraviolet light (tanning) and hormones.
- v. The nail is stratum corneum containing hard keratin and the nail root is covered by skin, and the nail body is the visible part of the nail. Nearly all of the nail is formed by the nail matrix, but the nail bed contributes.

- vi. Integumentary system is easily observed and often reflects events occurring in other parts of the body (e.g., cyanosis, jaundice, rashes).

## 6.0 TUTOR MARKED ASSIGNMENTS

1. The integumentary system
  - a. helps regulate body temperature.
  - b. is a site of fat storage.
  - c. is a site of vitamin E production.
  - d. eliminates large amounts of waste products from the body.
  - e. all of the above
  
2. A layer of skin (where mitosis occurs) that replaces cells lost from the outer layer of the epidermis is the
  - a. stratum corneum.
  - b. stratum basale.
  - c. stratum lucidum.
  - d. reticular layer.
  - e. subcutaneous tissue.

For questions 3–7, match the layer of the epidermis with the correct description or function:

  - a. stratum basale
  - b. stratum corneum
  - c. stratum granulosum
  - d. stratum lucidum
  - e. stratum spinosum
  
3. Production of keratin fibers; formation of lamellar bodies
4. Desquamation occurs; 25 or more layers of dead squamous cells
5. Production of cells; melanocytes produce and contribute melanin; hemidesmosomes present
6. Production of keratohyalin granules; lamellar bodies release lipids; cells die
7. Dispersion of keratohyalin around keratin fibers; layer appears transparent; cells dead
8. In which of these areas of the body is thick skin found?
  - a. back of the hand d. bridge of the nose
  - b. abdomen e. sole of the foot
  - c. over the shin

## 7.0 REFERENCE AND OTHER RESOURCES

Hutchinson, M., Mallat, J., Marieb, E.N., Wilhelm P.B. (2007). A Brief Atlas of the Human Body. Sna Franscisco: Pearson Education Inc.

Katherine M. A. Rogers and William N. Scott (2011) Nurses! Test Yourself in Anatomy and Physiology

Kathryn A. Booth, Terri. D. Wyman (2008) Anatomy, Physiology, and Pathophysiology for Allied Health

Keith L Moore, Persuade T.V.N (2018), The Developing Human Clinically Oriented Embryology 11th Edition Lippincott Williams & Wilkins

Kent M. Van De Graff, R.Ward Rhees, Sidney Palmer (2010) Schaum's Outline of human Anatomy and Physiology 3rd edition.

Philip Tate (2012) Seeley's Principles of Anatomy & Physiology 2nd ed.

Sadler T.W (2012), Langman's Medical Embryology 12th edition.

Seeley's Principles of Anatomy & Physiology, Second edition Published by McGraw-Hill, a business unit of The McGraw-Hill Companies, Inc., 1221 Avenue of the Americas, New York, NY 10020. Copyright c 2012- Chapter 17&18

## UNIT 2 THE TONGUE AND THE SENSE OF TASTE

### CONTENTS

- 1.0 Introduction
- 2.0 Objectives
- 3.0 Main Content
  - 3.1 Functions of Taste
  - 3.2 Location of Taste Buds
  - 3.3 Histology of Taste Buds
  - 3.4 Taste Preference and Control of Diet
  - 3.5 Clinical Correlates
- 4.0 Conclusion
- 5.0 Summary
- 6.0 Tutor-Marked Assignment
- 7.0 References/Further Reading

### 1.0 INTRODUCTION

Taste is mainly a function of the *taste buds* in the mouth, but it is common experience that one's sense of smell also contributes strongly to taste perception. In addition, the texture of food, as detected by tactual senses of the mouth, and the presence of substances in the food that stimulate pain endings, such as pepper, greatly alter the taste experience. The importance of taste lies in the fact that it allows a person to select food in accord with desires and often in accord with the body tissues' metabolic need for specific substances.

### 2.0 OBJECTIVES

At the end of this unit, you should be able to:

- discuss the anatomy of the tongue and the function of each part.
- describe how taste sensations are created and interpreted
- discuss the five primary taste sensations
- describe the histology and function of a typical taste bud
- explain the neuronal pathways for the sense of taste

### 3.0 MAIN CONTENT

#### 3.1 Functions of Taste

Substances called **tastants** dissolve in saliva, enter the taste pores, and by various mechanisms cause the taste cells to depolarize. For example, the diffusion of the positively charged ions Na<sup>+</sup> and H<sup>+</sup> into the taste

cells causes depolarization. The binding of tastants to receptors on the taste hairs activates G proteins, which results in depolarization by causing  $\text{Ca}^{2+}$  channels to open or  $\text{K}^{+}$  channels to close. When the taste cells depolarize, they release neurotransmitters that diffuse to sensory neurons associated with the taste cells. The neurotransmitters stimulate action potentials in the sensory neurons, which are conducted to the brain, where the sense of taste is perceived.

Five **primary tastes** have been identified in humans: salty, sour, sweet, bitter, and umami (a Japanese term loosely translated as savoury). The salty taste is stimulated by  $\text{Na}^{+}$ ; sour by acids; sweet by sugars, some other carbohydrates, and some proteins; bitter by alkaloids (bases); and umami by the amino acid glutamate and related compounds. The umami taste sensation is most intense when coupled with the salty taste, hence the popularity of adding salt to tomatoes, ketchup, soy sauce, and the additive monosodium glutamate (MSG). Even though only five primary tastes have been identified, humans can perceive a fairly large number of different tastes, presumably by combining the five basic taste sensations.

Thresholds for the five primary taste stimuli vary. Sensitivity for bitter substances is the highest. Many alkaloids are poisonous, and the high sensitivity for bitter tastes may be protective because of the avoidance of bitter foods. On the other hand, humans tend to crave sweet, salty, and umami tastes, perhaps in response to the body's need for sugars, carbohydrates, proteins, and minerals.

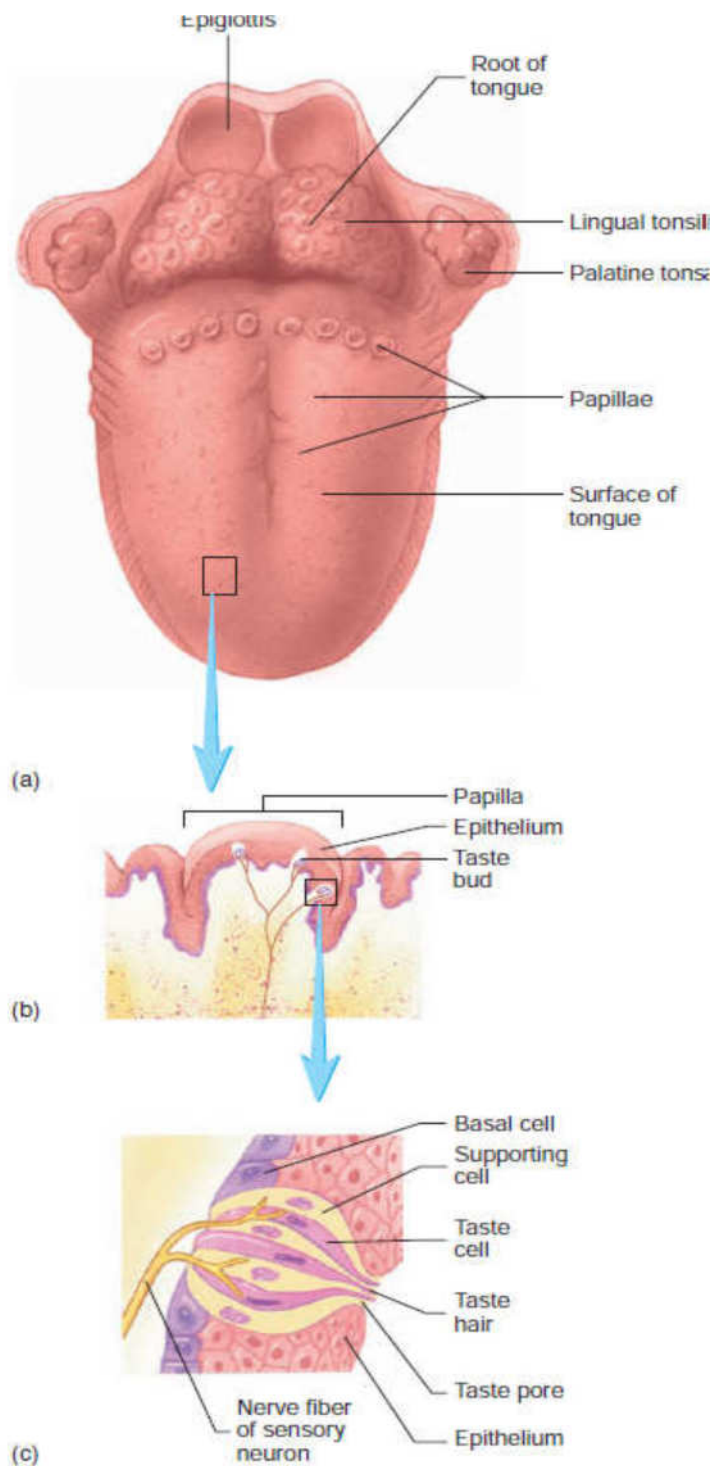
Many of the sensations thought of as being tastes are strongly influenced by olfactory sensations.

This phenomenon can be demonstrated by pinching one's nose to close the nasal passages while trying to taste something. With olfaction blocked, it is difficult to distinguish between the taste of a piece of apple and the taste of potato. Much of the "taste" is lost by this action. This is one reason that a person with a cold has a reduced sensation of taste. The tongue can detect other stimuli besides taste, such as temperature and texture, and these stimuli can influence the sensation of taste. Food served at the wrong temperature is perceived as distasteful. Stimulation of hot receptors by capsaicin or black pepper is interpreted as hot or spicy, and stimulation of cold receptors is perceived as fresh or minty.

### 3.2 Location of Taste Buds

The taste buds are found on three types of papillae of the tongue, as follows:

- A large number of taste buds are on the walls of the troughs that surround the circumvallate papillae, which form a V line on the surface of the posterior tongue.
  
- Moderate numbers of taste buds are on the fungiform papillae over the flat anterior surface of the tongue.
  
- Moderate numbers are on the foliate papillae located in the folds along the lateral surfaces of the tongue. Additional taste buds are located on the palate, and a few are found on the tonsillar pillars, on the epiglottis, and even in the proximal oesophagus. Adults have 3000 to 10,000 taste buds, and children have a few more. Beyond the age of 45 years, many taste buds degenerate, causing taste sensitivity to decrease in old age.



**Figure 13.2 Tongue, Papillae, and Taste Buds**  
 (a) Surface of the tongue. (b) A papilla. (c) A taste bud.

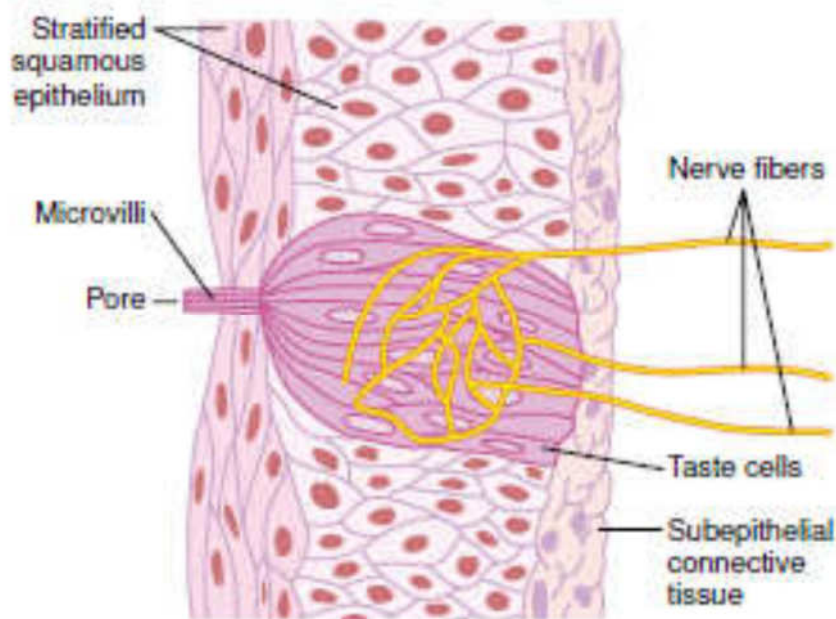
**Fig 2.1** Tongue, Papillae and Buds a) Surface of the tongue b) A papilla

c) A taste bud



### 3.3 Histology of Taste Buds

Each of the 10,000 taste buds on a person's tongue consists of three major types of specialised epithelial cells. The sensory cells of each taste bud consist of about 50 **taste cells**. Each taste cell has several microvilli, called **taste hairs**, extending from its apex into a tiny opening in the epithelium called the **taste pore**. The remaining two non-sensory cell types are **basal cells** and **supporting cells**. Like olfactory cells, the cells of the taste buds are replaced continuously, each having a normal life span of about 10 days.



**Fig.2.2: Taste Bud**

### 3.4 Taste Preference and Control of Diet

Taste preference simply means that an animal will choose certain types of food in preference to others, and the animal automatically uses this to help control the diet it eats. Furthermore, its taste preferences often change in accord with the body's need for certain specific substances.

The following experiments demonstrate this ability of animals to choose food in accord with the needs of their bodies. First, adrenalectomies, salt-depleted animals automatically select drinking water with a high concentration of sodium chloride in preference to pure water, and this is often sufficient to supply the needs of the body and prevent salt depletion death. Second, an animal given injections of excessive amounts of insulin develops a depleted blood sugar, and the animal automatically chooses the sweetest food from among many samples.

Third, calcium-depleted parathyroidectomies animals automatically choose drinking water with a high concentration of calcium chloride. Also, human beings reject any food that has an unpleasant affective sensation, which in many instances protects our bodies from undesirable substances. The phenomenon of taste preference almost certainly results from some mechanism located in the central nervous system and not from a mechanism in the taste receptors themselves, although the receptors often become sensitised in favour of a needed nutrient. An important reason for believing that taste preference is mainly a central nervous system phenomenon is that previous experience with unpleasant or pleasant tastes plays a major role in determining one's taste preferences. For instance, if a person becomes sick soon after eating a particular type of food, the person generally develops a negative taste preference, or taste aversion, for that particular food thereafter; the same effect can be demonstrated in lower animals.

### 3.5 Clinical Correlates

Much of what is perceived as a taste defect is truly a primary defect in olfaction resulting in an alteration in taste.

#### Self-Assessment Exercise (1)

- discuss the five primary taste sensations
- describe the histology and function of a typical taste bud
- explain the neuronal pathways for the sense of taste

#### Self-Assessment Exercise (2)

At the histology laboratory, examine the histological structure of the papillae with taste buds on the taste bud slide.

## 4.0 CONCLUSION

In this unit you learnt main function of the *taste buds* in the mouth, and the common experience that one's sense of smell also contributes strongly to taste perception.

## 5.0 SUMMARY

- Taste is mainly a function of the *taste buds* in the mouth, but it is common experience that one's sense of smell also contributes strongly to taste perception.
- Receptors on the hairs detect tastants (dissolved substances). Five basic types of taste exist: sour, salty, bitter, sweet, and umami.

- Taste buds usually are associated with papillae – circumvallate, fungiform and foliate papillae.
- Taste buds consist of taste cells, basilar cells, and supporting cells. The taste cells have taste hairs that extend into taste pores.
- Taste preference simply means that an animal will choose certain types of food in preference to others, and the animal automatically uses this to help control the diet it eats. Furthermore, its taste preferences often change in accord with the body's need for certain specific substances.

## 6.0 TUTOR MARKED ASSIGNMENT

1. Taste cells
  - a. are found only on the tongue.
  - b. extend through tiny openings called taste buds.
  - c. have no axons but release neurotransmitters when stimulated.
  - d. have axons that extend directly to the taste area of the cerebral cortex.
2. Which of these is *not* one of the basic tastes?
  - a. spicy
  - b. salty
  - c. bitter
  - d. umami
  - e. sour
3. What are the three kinds of lingual papillae, and where are they located?
4. Do taste receptors undergo adaptation?
5. Describe taste preference in relation to diet control.

## 7.0 REFERENCES/FURTHER READING

- Hutchinson, M., Mallat, J., Marieb, E.N., Wilhelm P.B. (2007). *A Brief Atlas of the Human Body*. Sna Franscisco: Pearson Education Inc.
- Katherine, M. A., Rogers & William, N. S. (2011). *Nurses! Test Yourself in Anatomy and Physiology*
- Kathryn, A. B. & Terri, D. W. (2008). *Anatomy, Physiology, and Pathophysiology for Allied Health*

Keith L Moore, Persuade T.V.N (2018), The Developing Human Clinically Oriented Embryology 11th Edition Lippincott Williams & Wilkins

Kent, M., Van De Graff, R., Ward Rhee & Sidney, Palmer (2010). Schaum's Outline of Human Anatomy and Physiology (3<sup>rd</sup> ed.).

Philip, Tate (2012). *Seeley's Principles of Anatomy & Physiology*. (2<sup>nd</sup> ed.).

Sadler T.W (2012), Langman's Medical Embryology 12th edition.

## **UNIT 3 THE NOSE AND THE SENSE OF SMELL**

### **CONTENTS**

- 1.0 Introduction
- 2.0 Objectives
- 3.0 Main Content
  - 3.1 Olfactory epithelium and bulb
  - 3.2 Threshold for detection of odors
  - 3.3 Neuronal pathways for olfaction
  - 3.4 Clinical correlates
- 4.0 Conclusion
- 5.0 Summary
- 6.0 Tutor-Marked Assignment
- 7.0 References/Further Reading

### **1.0 INTRODUCTION**

Smell is the least understood of our senses. This results partly from the fact that the sense of smell is a subjective phenomenon that cannot be studied with ease in lower animals. Another complicating problem is that the sense of smell is poorly developed in human beings in comparison with the sense of smell in many lower animals.

### **2.0 OBJECTIVES**

At the end of this unit, you should be able to:

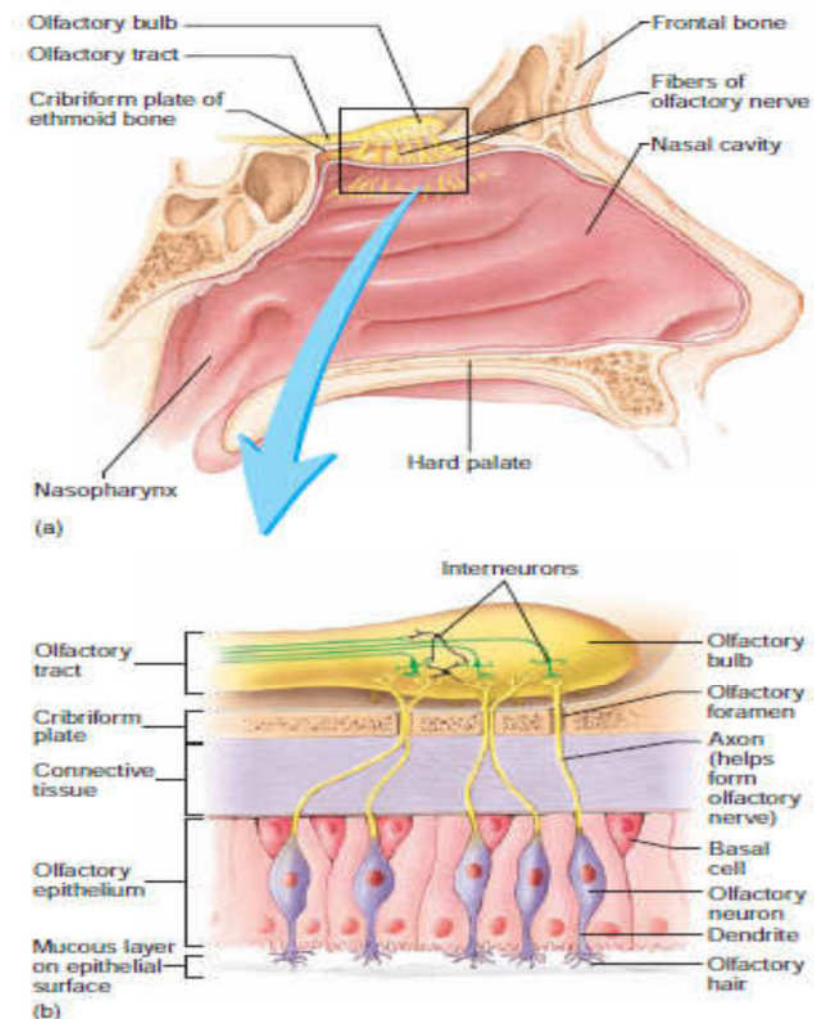
- describe the histological structure and function of the olfactory epithelium and the olfactory bulb
- explain how the perception of many different odours is possible
- Describe the neuronal pathways for the sense of smell.

### **3.0 MAIN CONTENT**

#### **3.1 Olfactory Epithelium and Bulb**

A small superior part of the nasal cavity is lined with olfactory epithelium. Ten million olfactory neurons are present within the olfactory epithelium. Olfactory neurons are bipolar neurons with dendrites extending to the epithelial surface of the nasal cavity. The ends of the dendrites are modified into bulbous enlargements with long, specialised cilia, called olfactory hairs, which lie in a thin mucous film on the epithelial surface. The mucus keeps the nasal epithelium moist, traps and dissolves molecules, and facilitates the removal of molecules and particles from the olfactory epithelium. Airborne odorants become

dissolved in the mucus on the surface of the epithelium and bind to molecules on the membranes of the olfactory hairs called **olfactory receptors**. The odorants must first be dissolved in fluid in order to reach the olfactory receptors. When an odorant binds to its receptor, a G protein associated with the receptor is activated. As a result of activation of the G protein,  $\text{Na}^+$  and  $\text{Ca}^{2+}$  channels in the membrane open. The influx of ions into the olfactory hairs results in depolarization and the production of action potentials in the olfactory Neurons. Once an odorant binds to its receptor, however, the receptor accommodates and does not respond to another odorant for some time.



**Fig 2.3** Olfactory Region, Epithelium and Bulb

### 3.2 Threshold for detection of odors

The threshold for the detection of odours is very low, so very few odorants bound to an olfactory neuron can initiate an action potential. Methylmercaptan, which has a nauseating odour similar to that of rotten cabbage, is added to natural gas at a concentration of about one part per

million. A person can detect the odour of about 1/25 billionth of a milligram of the substance and therefore is aware of the presence of the more dangerous but odourless natural gas. There are approximately 1000 different odorant receptors, which can react to odorants of different sizes, shapes, and functional groups. The average person can distinguish among approximately 4000 different smells. It has been proposed that the wide varieties of detectable odors are actually combinations of a smaller number of **primary odours**. The seven primary odours are camphoraceous (e.g., moth balls), musky, floral, peppermint, ethereal (e.g., fresh pears), pungent, and putrid. It is very unlikely, however, that this list is an accurate representation of all primary odours, and some studies point to the possibility of as many as 50 primary odours.

### 3.3 Neuronal Pathways for Olfaction

Axons from olfactory neurons form the **olfactory nerves (I)**, which pass through the olfactory foramina of the cribriform plate and enter the **olfactory bulb**. There they synapse with interneurons that relay action potentials to the brain through the **olfactory tracts**. Each olfactory tract terminates in the **olfactory cortex** and the **amygdala** in the temporal lobe. It is here that the sensation of smell is perceived. The olfactory cortex is part of the limbic system, projecting to the hypothalamus, amygdala, and hippocampus of the cerebrum. Odours can produce strong emotional reactions, memories, and other responses. For example, the perfume or cologne of a loved one can evoke good feelings, and memories and food odours can cause salivation and hunger. Within the olfactory bulb and olfactory cortex, feedback loops occur that tend to inhibit transmission of action potentials resulting from prolonged exposure to a given odorant. This feedback, plus the temporary decreased in sensitivity at the level of the receptors, results in adaptation to a given odour. For example, if you enter a room that has an odour, you are aware of the odour, but you adapt to the odour and cannot smell it as well after the first few minutes. If you leave the room for some time and then re - enter the room, the odour again seems more intense.

### 3.4 Clinical Correlates

- **Anosmia** - a complete loss of smell
- **Hyposmia** – partial loss of smell or decreased sensation of smell
- **Hyperosmia** – enhanced smell sensitivity
- **Dysosmia** – distortion in odour perception (includes parosmia and phantosmia)
- **Parosmia** – distortion of perception of an external stimulus
- **Phantosmia** – smell perception with no external stimulus.

**Common causes of smell disorders include:**

Aging, sinus and other respiratory infections, smoking, growths in nasal cavities, head injury, hormonal disturbances, dental problems, exposure to certain chemicals, such as insecticides and solvents, radiation for treatment of head and neck cancers.

**Self-Assessment Exercises**

1. At the histology laboratory, examine the olfactory cells slides under the microscope.
2. At the gross anatomy laboratory, identify the location of the olfactory epithelium and its relationship to the olfactory bulbs and the cribriform plate on the sagittal head model.

**4.0 CONCLUSION**

The ability to smell comes from specialized sensory cells, called olfactory sensory neurons, which are found in a small patch of tissue high inside the nose.

**5.0 SUMMARY**

- In this unit you have learnt that the sense of smell is a subjective phenomenon that cannot be studied with ease in lower animals
- Olfaction is the sense of smell.
- Olfactory neurons in the olfactory epithelium are bipolar neurons. Their distal ends have olfactory hairs. The olfactory hairs have receptors that respond to dissolved substances. There are approximately 1000 different odorant receptors.
- The receptors activate G proteins, which results in ion channels opening and depolarization.
- At least seven (perhaps 50) primary odours exist. The olfactory neurons have a very low threshold and accommodate rapidly.
- Axons from the olfactory neurons extend as olfactory nerves to the olfactory bulb, where they synapse with interneurons. Axons from these cells form the olfactory tracts, which connect to the olfactory cortex. The olfactory bulbs and cortex accommodate to odours.



## 6.0 TUTOR MARKED ASSIGNMENT

1. Olfactory neurons
  - a. have projections called cilia.
  - b. have axons that combine to form the olfactory nerves.
  - c. connect to the olfactory bulb.
  - d. have receptors that react with odorants dissolved in fluid.
  - e. all of the above.
2. What are the characteristics of an odorant—a chemical molecule that stimulates a smell receptor?
3. Does adaptation of smell receptors occur?
4. Do all of the volatile chemicals in the nose stimulate smell receptors?
- 4 Which of the cranial nerves innervate the olfactory mucosa?

## 7.0 REFERENCES/FURTHER READING

- Hutchinson, M., Mallat, J., Marieb, E.N., Wilhelm P.B. (2007). A Brief Atlas of the Human Body. Sna Franscisco: Pearson Education Inc.
- Katherine M. A. Rogers and William N. Scott (2011) Nurses! Test Yourself in Anatomy and Physiology
- Kathryn A. Booth, Terri. D. Wyman (2008) Anatomy, Physiology, and Pathophysiology for Allied Health
- Keith L Moore, Persuade T.V.N (2018), The Developing Human Clinically Oriented Embryology 11th Edition Lippincott Williams & Wilkins
- Kent M. Van De Graff, R.Ward Rhees, Sidney Palmer (2010) Schaum's Outline of human Anatomy and Physiology 3rd edition.
- Philip Tate (2012) Seeley's Principles of Anatomy & Physiology 2nd ed.
- Sadler T.W (2012), Langman's Medical Embryology 12th edition.
- Seeley's Principles of Anatomy & Physiology, Second edition Published by McGraw-Hill, a business unit of The McGraw-Hill Companies, Inc., 1221 Avenue of the Americas, New York, NY 10020. Copyright c 2012- Chapter 17&18

## UNIT 4 THE EAR AND SENSE OF HEARING AND BALANCE

### CONTENTS

- 1.0 Introduction
- 2.0 Objectives
- 3.0 Main Content
  - 3.1 Auditory Structures
  - 3.2 Auditory Functions
  - 3.3 Neuronal Pathways for Hearing and Balance
  - 3.4 Balance
  - 3.5 Clinical Correlates
- 4.0 Conclusion
- 5.0 Summary
- 6.0 Tutor-Marked Assignment
- 7.0 References/Further Reading

### 1.0 INTRODUCTION

The organs of hearing and balance are divided into three parts: the external, middle, and inner ear. The **external ear** is the part extending from the outside of the head to the **tympanic membrane**, or **eardrum**. The **middle ear** is an air-filled chamber medial to the tympanic membrane. The **inner ear** is a set of fluid-filled chambers medial to the middle ear. The external and middle ears are involved in hearing only, whereas the inner ear functions in both hearing and balance.

### 2.0 OBJECTIVES

At the end of this unit, you should be able to:

- describe the anatomy of the ear and the function of each part
- explain how sounds travel through the ear and are interpreted in the brain
- explain the role of the ear in maintaining equilibrium
- describe various disorders of the ear.

### 3.0 MAIN CONTENT

#### 3.1 Auditory Structures

##### External Ear/ Auricle

The auricle is the fleshy part of the external ear on the outside of the head. The auricle opens into the external acoustic meatus, a passageway that leads to the tympanic membrane. The auricle collects sound waves and directs them toward the external acoustic meatus, which transmits them to the tympanic membrane. The external acoustic meatus is lined with hairs and ceruminous glands, which produce cerumen, a modified sebum commonly called earwax. The hairs and cerumen help prevent foreign objects from reaching the delicate tympanic membrane.

The tympanic membrane is a thin membrane separating the external ear from the middle ear. It consists of a thin layer of connective tissue sandwiched between two epithelial layers. Sound waves reaching the tympanic membrane cause it to vibrate.

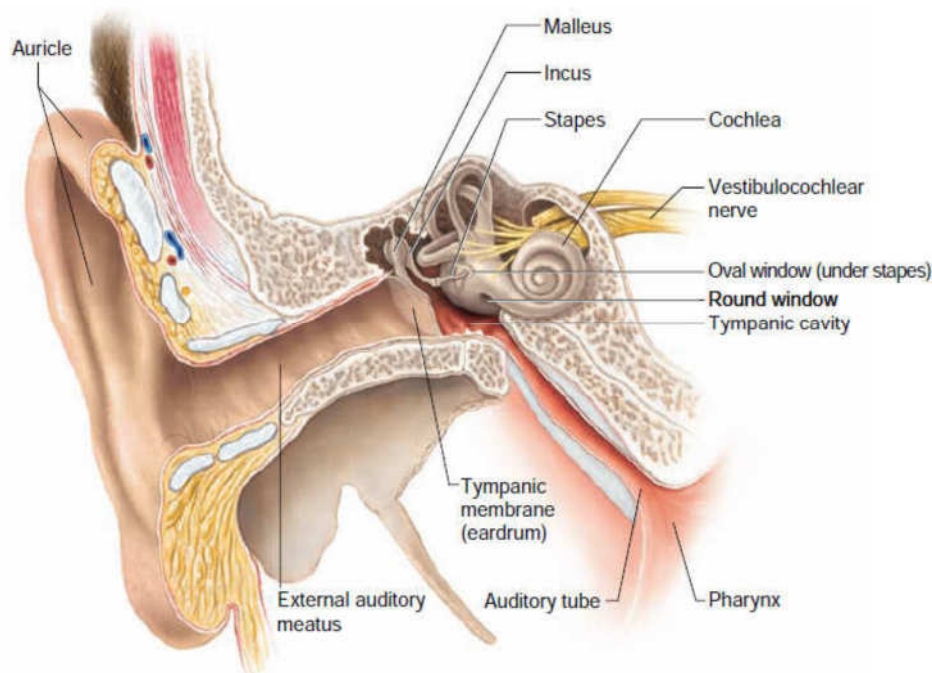
##### Middle Ear

Medial to the tympanic membrane is the air-filled cavity of the middle ear. Two covered openings, the **oval window** and the **round window** on the medial side of the middle ear, connect the middle ear with the inner ear. The middle ear contains three **auditory ossicles**: the **malleus**, **incus**, and **stapes**. These bones transmit vibrations from the tympanic membrane to the oval window. The malleus is attached to the medial surface of the tympanic membrane. The incus connects the malleus to the stapes. The base of the stapes is seated in the oval window and is surrounded by a flexible ligament. Two small muscles in the middle ear help dampen vibrations of the auditory ossicles caused by loud noises. The **tensor tympani** muscle is attached to the malleus and is innervated by the trigeminal nerve (V). The **stapedius** muscle is attached to the stapes and is innervated by the facial nerve (VII).

Two openings provide air passages from the middle ear. One passage opens into the **mastoid air cells** in the mastoid process of the temporal bone. The other passageway is the **auditory tube**, also called the **pharyngotympanic tube** or the **eustachian tube**. The auditory tube opens into the pharynx and enables air pressure to be equalised between the outside air and the middle ear cavity.

When a person changes altitude, air pressure outside the tympanic membrane changes relative to the air pressure in the middle ear. With an

increase in altitude, the pressure outside the tympanic membrane becomes less than the air pressure inside the middle ear and the tympanic membrane is pushed outward. With a decrease in altitude, the air pressure outside the ear becomes greater than in the middle ear and the tympanic membrane is pushed inward. Distortion of the tympanic membrane can make sounds seem muffled and stimulate pain. These symptoms can be relieved by opening the auditory tube to allow air to pass through the auditory tube to equalise air pressure. Swallowing, yawning, chewing, and holding the nose and mouth shut while gently trying to force air out of the lungs are methods used to open the auditory tube.



**Fig.3.1 Major Parts of the Ear**

### **Inner Ear**

The inner ear contains the sensory organs for hearing and balance. It consists of interconnecting, fluid-filled tunnels and chambers within the temporal bone called the bony labyrinth. The bony labyrinth is lined with endosteum. When the inner ear is drawn, it is the endosteum that is depicted. The bony labyrinth is divided into three regions: cochlea, vestibule, and semicircular canals. The vestibule and semicircular canals are involved primarily in balance, and the cochlea is involved in hearing. Inside the bony labyrinth is a similarly shaped but smaller set of membranous tunnels and chambers called the membranous labyrinth. The membranous labyrinth is filled with a clear fluid called endolymph, and the space between the membranous and bony labyrinths is filled with a fluid called perilymph. Perilymph is very similar to cerebrospinal

fluid, but endolymph has a high concentration of potassium and a low concentration of sodium, which is opposite from perilymph and cerebrospinal fluid. The membranous labyrinth of the cochlea separates the bony labyrinth into two parts. The cochlea is shaped like a snail shell—that is, a coiled tube.

The base of the cochlea connects to the vestibule and the apex of the cochlea is the end of the coiled tube. The bony core of the cochlea, around which the tube coils, is shaped like a screw with threads called the spiral lamina. A Y-shaped, membranous complex divides the cochlea into three portions. The base of the Y is the spiral lamina. One branch of the Y is the vestibular membrane, and the other branch is the basilar membrane. The space between these membranes is called the cochlear duct.

## 3.2 Auditory Functions

### Properties of Sound

Vibration of matter, such as air, water, or a solid material, creates sound. No sound occurs in a vacuum. For example, when a tuning fork vibrates, it causes the surrounding air to vibrate. The air vibrations consist of bands of compressed air followed by bands of less compressed air.

When these pressure changes are graphed through time, they have a wave form; hence, they are called sound waves. These sound waves are propagated through the air, somewhat as ripples are propagated over the surface of water. The **volume**, or loudness, of sound is a function of wave amplitude, or height, measured in decibels. The greater the amplitude is, the louder the sound. The **pitch** of sound is a function of the wave frequency. It is measured in hertz (Hz), which is the number of waves or cycles per second. The higher the frequency is, the higher the pitch. The normal range of human hearing is 20–20,000 Hz and 0 or more decibels (db). Sounds louder than 125 db are painful to the ear. Timbre is the resonance quality or overtones of a sound. A smooth sigmoid curve is the image of a “pure” sound wave, but such a wave almost never exists in nature. The sounds made by musical instruments and the human voice are not smooth sigmoid curves but, rather, are rough, jagged curves formed by numerous, superimposed curves of various amplitudes and frequencies.

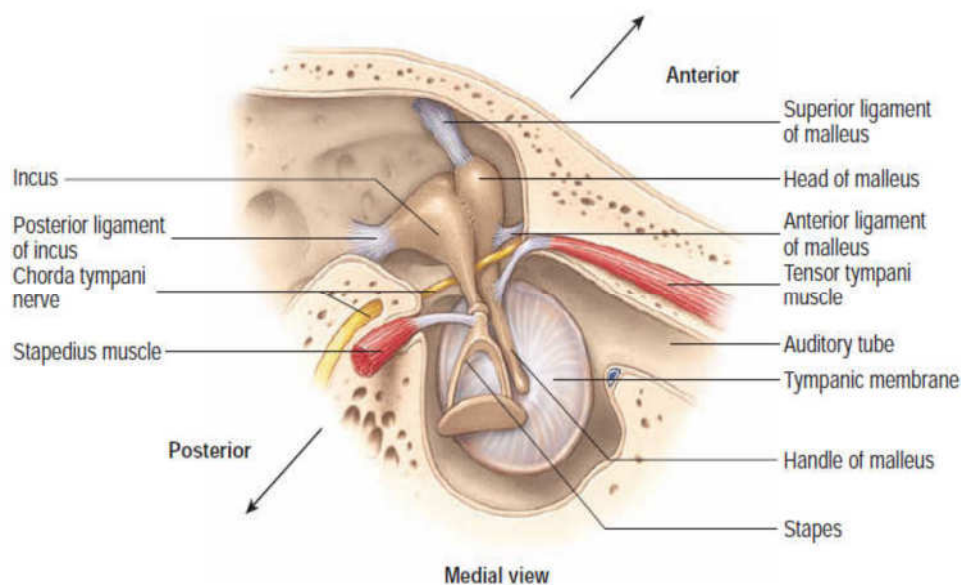
### External Ear

The auricle collects sound waves and directs them into the external acoustic meatus. Sound waves travel relatively slowly in air, 332 m/s, and a small time interval may elapse between the time a sound wave reaches one ear and the time it reaches the other. The brain can interpret

this interval to determine the direction from which a sound is coming. Sound waves are conducted through the external acoustic meatus and strike the tympanic membrane, causing it to vibrate.

## Middle Ear

Vibration of the tympanic membrane causes vibration of the three auditory ossicles of the middle ear, and by this mechanical linkage vibration is transferred to the oval window. The oval window is approximately 20 times smaller than the tympanic membrane. The mechanical force of vibration is amplified about 20-fold as it passes from the tympanic membrane through the auditory ossicles to the oval window because of this size difference. This amplification is necessary because more force is required to cause vibration in a liquid, such as the perilymph of the inner ear, than is required in air.



**Fig.3.2: Middle Ear**

## Middle Ear

The tensor tympani and stapedius muscles are attached to auditory ossicles. Excessively loud sounds cause these muscles to reflexively contract and dampen the movement of the auditory ossicles. This **sound attenuation reflex** protects the delicate inner ear structures from damage by loud noises. The sound attenuation reflex responds most effectively to low-frequency sounds and can reduce by a factor of 100 the energy reaching the oval window. The reflex is too slow to prevent damage from a sudden noise, such as a gunshot, and it cannot function effectively for longer than about 10 minutes, in response to prolonged noise.

## Inner Ear

As the stapes vibrates, it produces sound waves in the perilymph of the scala vestibuli. Vibrations of the perilymph are transmitted through the vestibular membrane and cause simultaneous vibrations of the endolymph. The mechanical effect is as though the perilymph and endolymph were a single fluid because the vestibular membrane is very thin. Vibration of the endolymph causes distortion of the basilar membrane, which is most important to hearing. As the basilar membrane moves, the hair cells resting on it move relative to the tectorial membrane, which remains stationary. The inner hair cell stereocilia are bent as they move against the tectorial membrane, resulting in the release of neurotransmitter and the production of action potentials in sensory neurons.

The basilar membrane is not uniform throughout its length. The membrane is narrower and denser near the oval window and wider and less dense near the apex of the cochlea. The various regions of the membrane can be compared to the strings in a piano, which has strings of varying length and thickness. As a result of this organisation, sounds with higher pitches cause the basilar membrane nearer the oval window to distort maximally, whereas sounds with lower pitches cause the basilar membrane nearer the apex of the cochlea to distort maximally. Depending on which hair cells are stimulated along the length of the basilar membrane, the brain interprets the pitch and timbre of sounds. Sound volume, or loudness, is a function of sound wave amplitude.

As the volume of sound increases, the vibration of the basilar membrane increases, the stimulation of hair cells increases, and the production of action potentials increases. The brain interprets the higher frequency of action potentials as a louder sound. The outer hair cells are involved in regulating the tension of the basilar membrane, thereby increasing the sensitivity of the inner ear to sounds. Stimulation of the inner hair cells by the nervous system stimulates the contraction of actin filaments within the hair cells, causing them to shorten. This adjustment in the height of the outer hair cells, attached to both the basilar membrane and the tectorial membrane, fine-tunes the tension of the basilar membrane and the distance between the basilar membrane and tectorial membrane. Sound waves in the perilymph of the scala vestibuli are also transmitted the length of the scala vestibuli and through the helicotrema into the perilymph of the scala tympani. This transmission of sound waves is probably of little consequence because the helicotrema is very small. Vibration of the basilar membrane produces most of the sound waves in the perilymph of the scala tympani. Sound waves in the scala tympani perilymph cause vibration of the membrane of the round window. Vibration of the round window membrane is important to hearing

because it acts as a mechanical release for sound waves within the scala tympani. If this window were solid, it would reflect the sound waves, which would interfere with and dampen later sound waves. The round window also allows the relief of pressure in the perilymph because fluid is not compressible, thereby preventing compression damage to the spiral organ.

### 3.3 Neuronal Pathway for Hearing and Balance

The axons of the sensory neurons supplying hair cells form the cochlear nerve. These sensory neurons are bipolar neurons, and their cell bodies are in the cochlear, or spiral, ganglion, located in the bony core of the cochlea. The cochlear nerve joins the vestibular nerve to become the vestibulocochlear nerve (VIII), which traverses the internal acoustic meatus and enters the cranial cavity. The special senses of hearing and balance are both transmitted by the vestibulocochlear (VIII) nerve.

The term *vestibular* refers to the vestibule of the inner ear, which is involved in balance. The term *cochlear* refers to the cochlea of the inner ear, which is involved in hearing. The vestibulocochlear nerve functions as two separate nerves carrying information from two separate but closely related structures. The auditory pathways within the CNS are very complex, with both crossed and uncrossed tracts. Unilateral CNS damage therefore usually has little effect on hearing. The neurons from the cochlear ganglion synapse with CNS neurons in the cochlear nucleus in the medulla oblongata. These neurons in turn either synapse in or pass through the superior olivary nucleus in the medulla oblongata. Neurons terminating in the superior olivary nucleus may synapse with efferent neurons returning to the cochlea to modulate pitch perception. Nerve fibers from the superior olivary nucleus also project to the trigeminal (V) nucleus, which controls the tensor tympani, and the facial (VII) nucleus, which controls the stapedius muscle. This is part of the sound attenuation reflex pathway.

Ascending neurons from the superior olivary nucleus synapse in the inferior colliculi, and neurons from there project to the thalamus, where they synapse with neurons that project to the cortex. These neurons terminate in the auditory cortex. Neurons from the inferior colliculi also project to the superior colliculi, where reflexes that turn the head and eyes in response to loud sounds are initiated.

#### Neuronal Pathways for Balance

The axons of the sensory neurons supplying hair cells of the maculae and crista ampullaris form the vestibular nerve. These sensory neurons are bipolar neurons, and their cell bodies are in the vestibular ganglion, a



swelling of the vestibulocochlear nerve located in the internal acoustic meatus. The sensory neurons terminate in the vestibular nucleus within the medulla oblongata. Axons run from this nucleus to numerous areas of the CNS, such as the spinal cord, the cerebellum, the cerebral cortex, and the nuclei controlling the extrinsic eye muscles.

Balance is a complex process not simply confined to one type of input. In addition to vestibular sensory input, the vestibular nucleus receives input from proprioceptive neurons throughout the body, as well as from the visual system. People are asked to close their eyes while balance is evaluated in a sobriety test because alcohol affects the proprioceptive and vestibular components of balance (cerebellar function) to a greater extent than it does the visual portion.

Reflex pathways exist between the dynamic balance part of the vestibular system and the nuclei controlling the extrinsic eye muscles (oculomotor, trochlear, and abducent). A reflex pathway allows the maintenance of visual fixation on an object while the head is in motion. This function can be demonstrated by spinning a person around about 10 times in 20 seconds, stopping him or her, and observing eye movements. A slight oscillatory movement of the eyes, called nystagmus, occurs. The eyes track in the direction of motion and return with a rapid recovery movement before repeating the tracking motion.

### **3.4 Balance**

The sense of balance, or equilibrium, has two components: static balance and dynamic balance. Static balance is associated with the vestibule and is involved in evaluating the position of the head relative to gravity. Dynamic balance is associated with the semicircular canals and is involved in evaluating changes in the direction and rate of head movements.

#### **Static balance**

Static balance is associated with the utricle and the saccule of the vestibule. It is primarily involved in evaluating the position of the head relative to gravity, although the system also responds to linear acceleration or deceleration, such as when a person is in a car that is increasing or decreasing speed. Most of the utricular and saccular walls consist of simple cuboidal epithelium. The utricle and saccule, however, each contain a specialised patch of epithelium about two to three mm in diameter called the macula. The macula of the utricle is oriented parallel to the base of the skull, and the macula of the saccule is perpendicular to the base of the skull. The maculae resemble the spiral organ and consist of hair cells, sensory neurons, and supporting cells. The “hairs” of the

hair cells consist of numerous microvilli, called **stereocilia**, and one cilium, called a **kinocilium**.

The stereocilia and kinocilium are embedded in the **otolithic membrane**, which is a gelatinous mass weighted with crystals of calcium carbonate and protein called **otoliths**. The otolithic membrane moves in response to gravity, bending the hair cells and initiating action potentials in their associated sensory neurons. The stereocilia function much as do the stereocilia of cochlear hair cells, with tip links connected to gated K<sup>+</sup> channels. Deflection of the hairs toward the kinocilium results in depolarization of the hair cell. The hair cells are constantly being stimulated at a low level by the presence of the otolith-weighted covering of the macula. When the otolithic membrane moves in response to gravity, the pattern and intensity of hair cell stimulation change. The change in action potentials produced is translated by the brain into specific information about head position or linear acceleration/deceleration. Much of this information is not perceived consciously but is dealt with subconsciously. The body responds by making subtle tone adjustments in the muscles of the back and neck, which are intended to restore the head to its proper neutral, balanced position.

### **Dynamic Balance**

Dynamic balance is associated with the semicircular canals and is involved in evaluating movements of the head. There are three **semicircular canals** placed at nearly right angles to one another. One semicircular canal lies nearly in the transverse plane, one in the frontal plane, and one in the sagittal plane. The arrangement of the semicircular canals enables a person to detect movement in all directions. The base of each semicircular canal is expanded into an **ampulla**. Within each ampulla, the epithelium is specialised to form a **crista ampullaris**. This specialised sensory epithelium is structurally and functionally very similar to the sensory epithelium of the maculae.

Each crista consists of a ridge or crest of epithelium with a curved, gelatinous mass, the **cupula**, suspended over the crest. The hair like processes of the crista hair cells, which are stereocilia similar to those in the maculae and cochlear hair cells, are embedded in the cupula. The cupula contains no otoliths and therefore does not respond to gravitational pull. Instead, the cupula is a float that is displaced by endolymph movements within the semicircular canals. As the head begins to move, the endolymph does not move at the same rate as the semicircular canals, which are part of the temporal one. This difference causes displacement of the cupula in a direction opposite to that of the movement of the head. To appreciate this effect, imagine holding a

feather (the cupula) in your hand (the crista ampullaris). If you rapidly move your hand, the feather bends over in the direction opposite the movement as it drags through the air (endolymph). The bending of the stereocilia results in the stimulation of sensory neurons. The brain interprets the direction of head movement based on which hair cells in which crista ampullaris are stimulated. The semicircular canals detect changes in the rate of movement rather than movement alone because displacement of the cupula is most intense when the rate of head movement changes rapidly. As with the static balance, the information the brain obtains regarding dynamic balance is largely subconscious.

If a person continually spins in one direction, the endolymph of the semicircular canals begins to move and catches up with the cupula, and stimulation is stopped. If spinning suddenly stops, the endolymph continues to move because of its momentum, causing displacement of the cupula in the same direction as the head had been moving. The brain interprets this movement of the cupula to mean the head is moving in the opposite direction of the spin, even though the head is no longer moving. This is why a person has a feeling of moving even after he or she has stopped spinning.

### 3.5 Clinical Correlates

- **Tympanic Membrane Rupture**

Rupture of the tympanic membrane may result in hearing impairment. Foreign objects thrust into the ear, pressure, and infections of the middle ear can rupture the tympanic membrane. Sufficient differential pressure between the middle ear and the outside air can also rupture the tympanic membrane. This can occur in flyers, divers, or individuals who are hit on the side of the head by an open hand.

- **Chorda Tympani**

The chorda tympani is a branch of the facial nerve carrying taste impulses from the anterior two-thirds of the tongue. It crosses through the middle ear between the malleus and incus. The chorda tympani have nothing to do with hearing but is just passing through. This nerve can be damaged, however, during ear surgery or by a middle ear infection, resulting in loss of taste sensation from the anterior two-thirds of the tongue on the side innervated by that nerve.

- **Human Speech and Hearing Impairment**

The range of normal human speech is 250–8000 Hz. This is the range that is tested for the possibility of hearing impairment because it is the most important for communication.

- **Loud Noises and Hearing Loss**

Prolonged or frequent exposure to excessively loud noises can cause degeneration of the spiral organ at the base of the cochlea, resulting in high-frequency deafness. The actual amount of damage can vary greatly from person to person. High-frequency loss can cause a person to miss hearing consonants in a noisy setting. Loud music, amplified to 120 db, can impair hearing. The defects may not be detectable on routine diagnosis, but they include decreased sensitivity to sound in specific narrow frequency ranges and a decreased ability to discriminate between two pitches. Loud music, however, is not as harmful as is the sound of a nearby gunshot, which is a sudden sound occurring at 140 db. The sound is too sudden for the attenuation reflex to protect the inner ear structures, and the intensity is great enough to cause auditory damage. In fact, gunshot noise is the most common recreational cause of serious hearing loss.

- **Meniere Disease**

Meniere disease is the most common disease involving dizziness from the inner ear. Its cause is unknown but it appears to involve a fluid abnormality in one (usually) or both ears. Symptoms include vertigo, hearing loss, tinnitus, and a feeling of “fullness” in the affected ear.

Treatment includes a low-salt diet and diuretics (water pills). Symptoms may also be treated with medications for motion sickness.

### **Self-Assessment Exercises**

- describe the anatomy of the ear and the function of each part
- explain how sounds travel through the ear and are interpreted in the brain
- explain the role of the ear in maintaining equilibrium
- describe various disorders of the ear.

## **4.0 CONCLUSION**

The organs of hearing and balance are divided into three parts: the external, middle, and inner ear

## 5.0 SUMMARY

In this unit you learnt

- The osseous labyrinth is a canal system within the temporal bone that contains perilymph and the membranous labyrinth. Endolymph is inside the membranous labyrinth.
- The external ear consists of the auricle and external acoustic meatus. The middle ear connects the external and inner ears. The tympanic membrane is stretched across the external acoustic meatus.
- The malleus, incus, and stapes connect the tympanic membrane to the oval window of the inner ear.
- The auditory tube connects the middle ear to the pharynx and equalises pressure. The middle ear is connected to the mastoid air cells. The inner ear has three parts: the semicircular canals; the vestibule, which contains the utricle and the saccule; and the cochlea.
- The cochlea is a spiral-shaped canal within the temporal bone. The cochlea is divided into three compartments by the vestibular and basilar membranes. The scala vestibuli and scala tympani contain perilymph. The cochlear duct contains endolymph and the spiral organ.
- The spiral organ consists of inner hair cells and outer hair cells, which attach to the tectorial membrane.
- Pitch is determined by the frequency of sound waves and volume by the amplitude of sound waves. Timbre is the resonance quality (overtones) of sound.
- Axons from the vestibulocochlear nerve synapse in the medulla. Neurons from the medulla project axons to the inferior colliculi, where they synapse. Neurons from this point project to the thalamus and synapse. Thalamic neurons extend to the auditory cortex.

## 6.0 TUTOR MARKED ASSIGNMENT

1. Name the three parts of the ear, and state their functions.
2. Describe the structural components of the *middle ear* and their functions.
3. Which of these structures is found within or is a part of the external ear?
  - a. oval window
  - b. auditory tube
  - c. ossicles

- d. external acoustic meatus
  - e. cochlear duct
4. Given these auditory ossicles:
- 1 incus
  - 2 malleus
  - 3 stapes

Choose the arrangement that lists the auditory ossicles in order from the tympanic membrane to the inner ear.

- a. 1,2,3
  - b. 1,3,2
  - c. 2,1,3
  - d. 2,3,1
  - e. 3,2,1
5. The spiral organ is found within the
- a. cochlear duct.
  - b. scala vestibuli.
  - c. scala tympani.
  - d. vestibule.
  - e. semicircular canals.
6. An increase in the loudness of sound occurs as a result of an increase in the sound wave.
- a. frequency
  - b. amplitude
  - c. resonance
  - d. both a and b
7. Interpretation of different sounds is possible because of the ability of it to vibrate at different frequencies and stimulate the:
- a. vestibular membrane, vestibular nerve
  - b. vestibular membrane, spiral organ
  - c. basilar membrane, vestibular nerve
  - d. basilar membrane, spiral organ

## 7.0 REFERENCES/FURTHER READING

Hutchinson, M., Mallat, J., Marieb, E.N., Wilhelm P.B. (2007). A Brief Atlas of the Human Body. Sna Franscisco: Pearson Education Inc.

Katherine M. A. Rogers and William N. Scott (2011) Nurses! Test Yourself in Anatomy and Physiology

Kathryn A. Booth, Terri. D. Wyman (2008) Anatomy, Physiology, and Pathophysiology for Allied Health

Keith L Moore, Persuade T.V.N (2018), The Developing Human Clinically Oriented Embryology 11th Edition Lippincott Williams & Wilkins

Kent M. Van De Graff, R.Ward Rhees, Sidney Palmer (2010) Schaum's Outline of human Anatomy and Physiology 3rd edition.

Philip Tate (2012) Seeley's Principles of Anatomy & Physiology 2nd ed.

Sadler T.W (2012), Langman's Medical Embryology 12th edition.

Seeley's Principles of Anatomy & Physiology, Second edition Published by McGraw-Hill, a business unit of The McGraw-Hill Companies, Inc., 1221 Avenue of the Americas, New York, NY 10020. Copyright c 2012- Chapter 17&18

## UNIT 5 THE EYES AND THE SENSE OF VISION

### CONTENTS

- 1.0 Introduction
- 2.0 Objectives
- 3.0 Main Content
  - 3.1 Anatomy of the Eye
  - 3.2 Functions of the Eye
  - 3.3 Visual Pathway
  - 3.4 Clinical Correlates
- 4.0 Conclusion
- 5.0 Summary
- 6.0 Tutor-Marked Assignment
- 7.0 References/Further Reading

### 1.0 INTRODUCTION

The visual system includes the eyes, the accessory structures, and the sensory neurons that project to the cerebral cortex where action potentials conveying visual information are interpreted. The **eye** consists of the **eyeball**, or globe of the eye, and the optic nerve. Much of the information we obtain about the world around us is detected by the visual system. Our education is largely based on visual input and depends on our ability to read words and numbers. Visual input includes information about light and dark, movement, colour and hue.

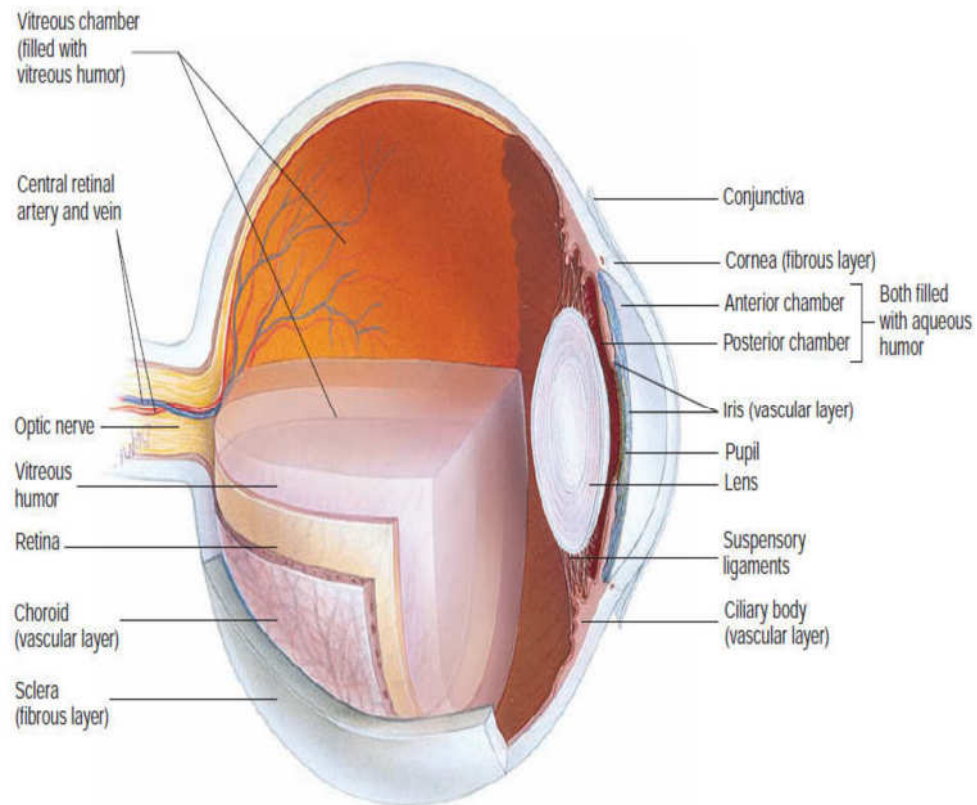
### 2.0 OBJECTIVES

At the end of this unit, you should be able to:

- list the accessory structures of the eye, and explain their functions
- describe the anatomy of the eye
- describe the focusing system of the eye and how it adjusts to see distant and near objects
- explain the structure of the retina, and how light entering the eye results in action potentials in the optic nerve
- outline the neuronal pathways for vision.



### 3.1 Anatomy of the Eye



**Fig. 4.1: Sagittal Section of the Eye**

The eyeball is composed of three layers. From superficial to deep they are the **fibrous layer**, **vascular layer**, and **retina**. The fibrous layer consists of the sclera and cornea; the vascular layer consists of the choroid, ciliary body, and iris.

#### Fibrous Layer

The **sclera** is the firm, opaque, white, outer layer of the posterior five-sixths of the eyeball. It consists of dense collagenous connective tissue with elastic fibers. The sclera helps maintain the shape of the eyeball, protects its internal structures, and provides an attachment point for the extrinsic eye muscles. A small portion of the sclera can be seen as the “white of the eye”.

The sclera is continuous with the **cornea**, the anterior sixth of the eyeball. The cornea is avascular and transparent, permitting light to enter the eye. The focusing system of the eye refracts, or bends, light and focuses it on the nervous layer (retina). The cornea is responsible for most of the refraction of light entering the eye.

The cornea consists of a connective tissue matrix containing collagen, elastic fibers, and proteoglycans, with a layer of stratified squamous

epithelium covering the outer surface and a layer of simple squamous epithelium on the inner surface. The outer epithelium is continuous with the conjunctiva over the sclera. The transparency of the cornea results from its low water content. In the presence of water, proteoglycans trap water and expand, which scatters light. In the absence of water, the proteoglycans decrease in size and do not interfere with the passage of light through the matrix.

### **Vascular Layer**

The vascular layer of the eye is so named because it contains most of the blood vessels of the eye. The posterior portion of the vascular layer, associated with the sclera, is the **choroid**. This is a very thin structure consisting of a vascular network and many melanin-containing pigment cells so that it appears black in colour. The black colour absorbs light so that it is not reflected inside the eye. If light were reflected inside the eye, the reflection would interfere with vision. The interiors of cameras are black for the same reason.

The choroid is continuous anteriorly with the ciliary body, which consists of an outer ciliary ring and an inner group of ciliary processes. The ciliary ring and the base of the ciliary processes contain smooth muscle called ciliary muscles. Suspensory ligaments attach the ciliary ring and processes to the lens of the eye, and contraction of the ciliary muscles can change the shape of the lens. The ciliary process also produces aqueous humour. The ciliary body is continuous anteriorly with the iris of the eye, which is the “coloured part” of the eye. The iris is a contractile structure, consisting mainly of smooth muscle, surrounding an opening called the pupil. Light enters the eye through the pupil, and the iris regulates the amount of light by controlling the size of the pupil. The iris contains two groups of smooth muscles: a circular group called the sphincter pupillae and a radial group called the dilator pupillae. The sphincter pupillae are innervated by parasympathetic fibers from the oculomotor nerve (III). When they contract, the pupil constricts and less light enters the eye. The dilator pupillae are innervated by sympathetic fibers. When they contract, the pupil dilates and more light enters the eye. The ciliary muscles, sphincter pupillae, and dilator pupillae are sometimes referred to as the intrinsic eye muscles.

The colour of the eye differs from person to person. A large amount of melanin in the iris causes it to appear brown or even black. Less melanin results in light brown, green, or gray irises. Even less melanin causes the eyes to appear blue. If there is no pigment in the iris, as in albinism, the iris is pink because blood vessels in the eye reflect light back to the iris. The genetics of eye colour is quite complex.

## Retina

The retina is the inner layer of the eye, covering the inner surface of the eye posterior to the ciliary body. The retina has over 126 million photoreceptor cells, which respond to light. As a result, action potentials are generated and conducted by the optic nerve (II) out of the eye to the cerebral cortex, where the sense of vision takes place. When the posterior region of the retina is examined with an ophthalmoscope, several important features can be observed. Near the center of the posterior retina is a small, yellow spot approximately four (4) mm in diameter, the macula.

In the center of the macula is a small pit, the fovea centralise. The fovea, followed by the macula, has the highest concentration of photoreceptor cells in the retina. Thus, they are the part of the retina most sensitive to light. Just medial to the macula is a white spot, the optic disc, through which the central retinal artery enters and the central retinal vein exits the eyeball. Branches from these vessels spread over the surface of the retina. The optic disc is also the place where axons from the neurons of the retina converge to form the optic nerve, which exits the posterior eye.

The optic disc contains only axons and no photoreceptor cells. Therefore, it does not respond to light and is called the blind spot of the eye.

## Chambers of the Eye

The interior of the eye is divided into three chambers: **anterior chamber**, **posterior chamber**, and **vitreous chamber**. The anterior and posterior chambers are located between the cornea and the lens. The iris separates the anterior chamber from the posterior chamber, which are continuous with each other through the pupil. The much larger vitreous chamber is posterior to the lens. A fluid called **aqueous humour** fills the anterior and posterior chambers. Aqueous humour helps maintain intraocular pressure, which keeps the eyeball inflated and is largely responsible for maintaining the shape of the eyeball. The aqueous humour also refracts light and provides nutrition for the structures of the anterior chamber, such as the cornea, which has no blood vessels. Aqueous humour is produced by the ciliary processes as a blood filtrate and is returned to the circulation through a venous ring called the **scleral venous sinus** (canal of Schlemm) (shlem), which is located at the junction of the sclera and cornea. The production and removal of aqueous humour result in the “circulation” of aqueous humour and maintenance of a constant intraocular pressure.

**Glaucoma** is an abnormal increase in intraocular pressure that results when the rate of production of aqueous humour exceeds its rate of removal. A transparent, jellylike substance called **vitreous humour** fills the vitreous chamber. The vitreous humour helps maintain intraocular pressure and therefore the shape of the eyeball, and it holds the lens and retina in place. It also functions in the refraction of light in the eye. Vitreous humour is not produced as rapidly as is the aqueous humour, and its turnover is extremely slow.

## Lens

The **lens** is an avascular, transparent, biconvex disk located behind the pupil. *Biconvex* means that each side of the lens bulges outward. The lens is part of the focusing system of the eye, and light passing through the lens is focused on the retina. The lens is a flexible structure, and changing the shape of the lens is involved with adjusting the focus of light. The lens consists of a layer of cuboidal epithelial cells on its anterior surface and a posterior region of very long, columnar epithelial cells called **lens fibers**. Cells from the anterior epithelium proliferate and give rise to the lens fibers. The lens fibers lose their nuclei and other cellular organelles and accumulate a set of proteins called **crystalline**. A highly elastic, transparent **lens capsule** surrounds the lens. The suspensory ligaments connect the lens capsule to the ciliary body. Through the lens capsule and the suspensory ligaments, the ciliary body can change the shape of the lens.

## Accessory Structures

Accessory structures protect, lubricate, and move the eye. They include the eyebrows, eyelids, conjunctiva, lacrimal apparatus, and extrinsic eye muscles.

## Eyebrows

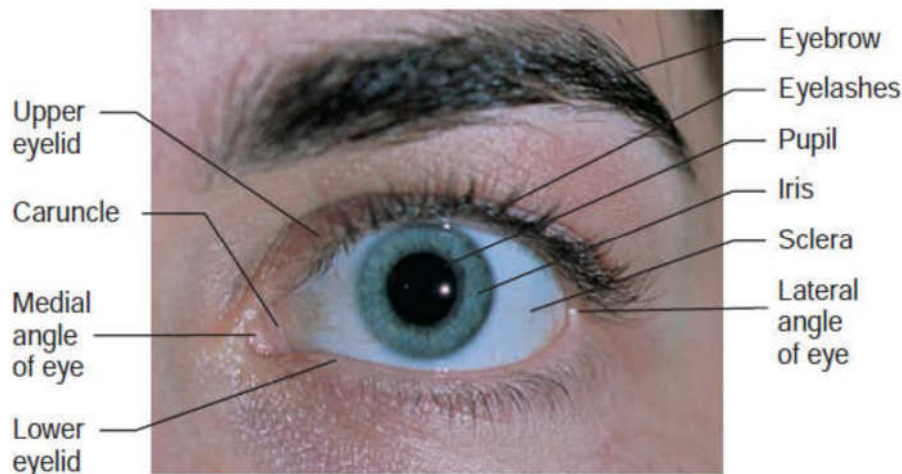
The **eyebrows** are curved lines of hair over the orbit. They protect the eyes by preventing perspiration, which can irritate the eyes, from running down the forehead and into them, and they help shade the eyes from direct sunlight.

## Eyelids

The **eyelids** are moveable folds covering the anterior surface of the eye when closed. The upper and lower eyelids meet at the **medial** and **lateral angles of the eye**. The medial angle contains a small, reddishpink mound called the **caruncle**. The caruncle contains some

modified sebaceous and sweat glands. The **eyelids** consist of five layers of tissue. From the outer to the inner surface, they are (1) a thin layer of skin on the external surface; (2) a thin layer of loose connective tissue; (3) a layer of skeletal muscle consisting of the orbicularis oculi and levator palpebrae superioris muscles; (4) a crescent-shaped layer of dense connective tissue called the **tarsal plate**, which helps maintain the shape of the eyelid; and (5) the conjunctiva.

The eyelids, with their associated lashes, protect the eyes from foreign objects. If an object suddenly approaches the eye, the eyelids protect the eye by rapidly closing and then opening, a response called the blink reflex. Blinking, which normally occurs about 25 times per minute, also helps keep the eye lubricated by spreading tears over the surface. Movements of the eyelids are a function of skeletal muscles. The orbicularis oculi muscle closes the lids, and the levator palpebrae superioris elevates the upper lid. The eyelids also help regulate the amount of light entering the eye. **Eyelashes** are attached as a double or triple row of hairs to the free edges of the eyelids. **Ciliary glands** are modified sweat glands that open into the hair follicles of the eyelashes to keep them lubricated. When one of these glands becomes inflamed, it is called a **sty**. **Tarsal glands**, or **meibomian glands**, are sebaceous glands near the inner margins of the eyelids. They produce **sebum**, an oily, semifluid substance that lubricates the lids and restrains tears from flowing over the margin of the eyelids. An infection or a blockage of a tarsal gland is called a **chalazion**, or **meibomian cyst**.



**Fig. 4.2: The Left Eye and Accessory Structures.**

### Conjunctiva

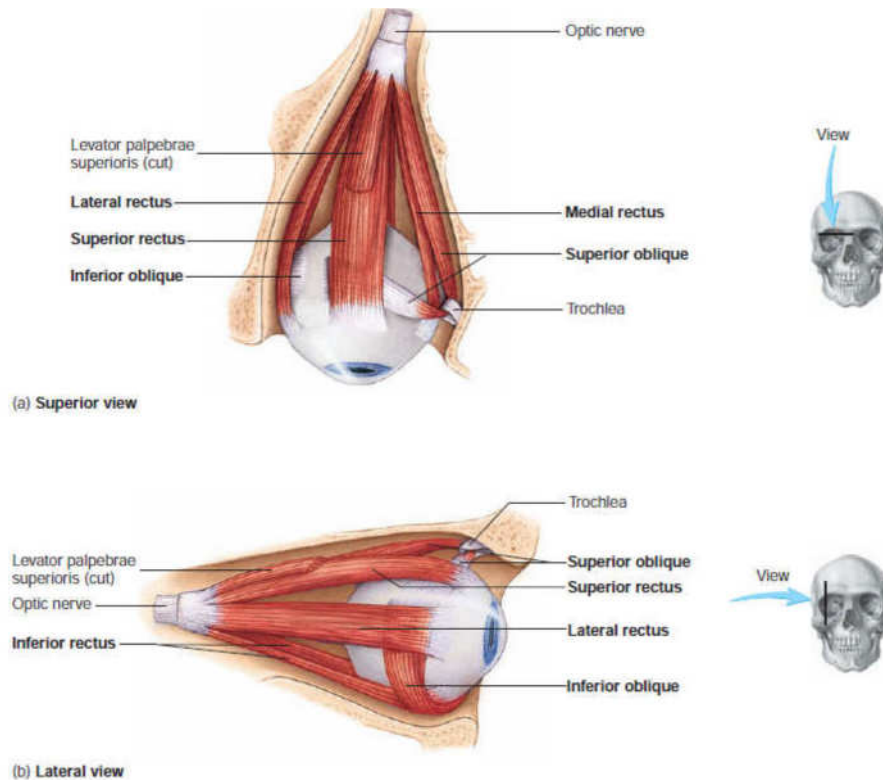
The **conjunctiva** is a thin, transparent mucous membrane. It covers the inner surface of the eyelids and the anterior white surface of the eye. The conjunctiva reduces friction as the eyelids move over the surface of the eye. It also is a barrier to the entry of microorganisms.

## Lacrimal Apparatus

The **lacrimal apparatus** consists of a lacrimal gland, lacrimal canaliculi, and a nasolacrimal duct. The lacrimal apparatus produces tears, releases the tears onto the surface of the eye, and removes excess tears from the surface. The **lacrimal gland** is in the superolateral corner of the orbit and is innervated by parasympathetic fibers from the facial nerve (VII). The lacrimal gland produces tears, which leave the gland through several **lacrimal ducts** and pass over the anterior surface of the eyeball. The lacrimal gland produces tears constantly at the rate of about one (1) mL/day to moisten the surface of the eye, lubricate the eyelids, and wash away foreign objects. Tears are mostly water, with some salts, mucus, and lysozyme, an enzyme that kills certain bacteria. Most of the fluid produced by the lacrimal glands evaporates from the surface of the eye, but excess tears are collected in the medial corner of the eye by small tubes called the **lacrimal canaliculi**. One lacrimal canaliculus opens on the inner, medial surface of the upper eyelid, and the other lacrimal canaliculus opens on the inner, medial surface of the lower eyelid. The lacrimal canaliculi connect to the **nasolacrimal duct**, which opens into the inferior meatus of the nasal cavity beneath the inferior nasal concha.

## Extrinsic Eye Muscles

The **extrinsic eye muscles** attach to the outside of the eyeball and cause it to move. There are four rectus muscles, the **superior, inferior, medial, and lateral rectus muscles**.



**Fig. 4.3: The Extrinsic Muscles of the Right Eye**

**Rectus** means straight, and the fibers of these muscles are nearly straight with the anterior-posterior axis of the eyeball. There are two oblique muscles, the **superior** and **inferior oblique muscles**, so named because they are at an angle to the axis of the eyeball. The movements of the eye can be described graphically by a figure resembling the letter **H**. The clinical test for normal eye movement is therefore called the **H test**. A person's inability to move the eye toward one part of the **H** may indicate dysfunction of an extrinsic eye muscle or the cranial nerve to the muscle. The superior oblique muscle is innervated by the trochlear nerve (IV). The nerve is so named because the superior oblique muscle goes around a little pulley, or trochlea, in the superomedial corner of the orbit. The lateral rectus muscle is innervated by the abducent nerve (VI), so named because the lateral rectus muscle abducts the eye. The other four extrinsic eye muscles are innervated by the oculomotor nerve (III).

### 3.2 Functions of the Eye

The eye receives light and produces action potentials. When the brain interprets the action potentials, it results in vision.

#### Properties of Light

The **electromagnetic spectrum** is the entire range of wavelengths, or frequencies, of electromagnetic radiation. Gamma waves have the shortest wavelength and radio waves the longest wavelength. **Visible**

**light**, the portion of the electromagnetic spectrum that can be detected by the human eye, is a small part of the electromagnetic spectrum. Within the visible spectrum, each colour has a different wavelength. An important characteristic of light is that it can be refracted, or bent. As light passes from air to a denser substance, such as glass or water, its speed is reduced. If the surface of that substance is at an angle other than 90 degrees to the direction the light rays are traveling, the rays are bent as a result of variation in the speed of light as it encounters the new medium. This bending of light is called **refraction**. The greater the curvature of the surface, the greater is the refraction of light. If the surface of a lens is concave, with the lens thinnest in the center, the light rays diverge as a result of refraction. If the surface is convex, with the lens thickest in the center, the light rays converge. As light rays converge, they finally reach a point at which they cross. This point is called the **focal point (FP)**, and causing light to converge is called **focusing**.

If light rays strike an object that is not transparent, they bounce off the surface. This phenomenon is called **reflection**. The images we see result from light reflected from objects.

### **The Eye as a Camera**

The eye is optically equivalent to the usual photographic camera. It has a lens system, a variable aperture system (the pupil), and a retina that corresponds to the film. The lens system of the eye is composed of four refractive interfaces: (1) the interface between air and the anterior surface of the cornea, (2) the interface between the posterior surface of the cornea and the aqueous humour, (3) the interface between the aqueous humour and the anterior surface of the lens of the eye, and (4) the interface between the posterior surface of the lens and the vitreous humour. The internal index of air is 1; the cornea, 1.38; the aqueous humour, 1.33; the crystalline (on average), 1.40; and the vitreous humour, 1.34.

### **Focusing System of the Eye**

The light entering the eye passes through the focusing system of the eye to strike the retina. The **focusing system of the eye**, which refracts light, is the cornea, aqueous humour, lens, and vitreous humour. Light passing through the focusing system is refracted, producing a focal point. No image is produced at the focal point. Past the focal point is a place where the image passing through the focusing system can be clearly seen. In a normal eye, the focused image falls on the retina. The image is inverted and reversed right to left because the light rays cross at the focal point.



The cornea and lens are the most important elements of the focusing system of the eye. The cornea is responsible for most of the refraction of light because the greatest contrast in media density is between the air and the cornea. The shape of the cornea and its distance from the retina are fixed, however, so that no adjustment in the location of the focused image can be made by the cornea. Fine adjustments to the location of the focused image are accomplished by changing the shape of the lens. Increasing the curvature of the lens increases the refraction of light, moving the focused image closer to the lens. Decreasing the curvature of the lens decreases the refraction of light, moving the focused image farther from the lens. In cameras, microscopes, and telescopes, focusing is not accomplished by changing lens shape. Instead, focusing is accomplished by moving the lens closer to or farther from the point at which the image will be focused.

### **Distant and Near Vision**

**Distant vision** occurs when looking at objects 20 feet or more from the eye, whereas **near vision** occurs when looking at objects that are less than 20 feet from the eye. In distant vision, the ciliary muscles in the ciliary body are relaxed. The suspensory ligaments, however, maintain elastic pressure on the lens, thereby keeping it relatively flat. The condition in which the lens is flattened so that nearly parallel rays from a distant object are focused on the retina is referred to as **emmetropia** and is the normal resting condition of the lens. The point at which the lens does not have to thicken for focusing to occur is called the **far point of vision** and normally is 20 feet or more from the eye. When an object is brought closer than 20 feet to the eye, the image falling on the retina is no longer in focus. Three events occur to bring the image into focus on the retina: accommodation by the lens, constriction of the pupil, and convergence of the eyes.

1. *Accommodation.* When the eye focuses on a nearby object, the ciliary muscles contract as a result of parasympathetic stimulation from the oculomotor nerve (III). This sphincter like contraction pulls the choroid toward the lens to reduce the tension on the suspensory ligaments. This allows the lens to assume a more spherical form because of its own elastic nature. The more spherical lens has a more convex surface, causing greater refraction of light, which brings the image back into focus on the retina. This process is called **accommodation**.

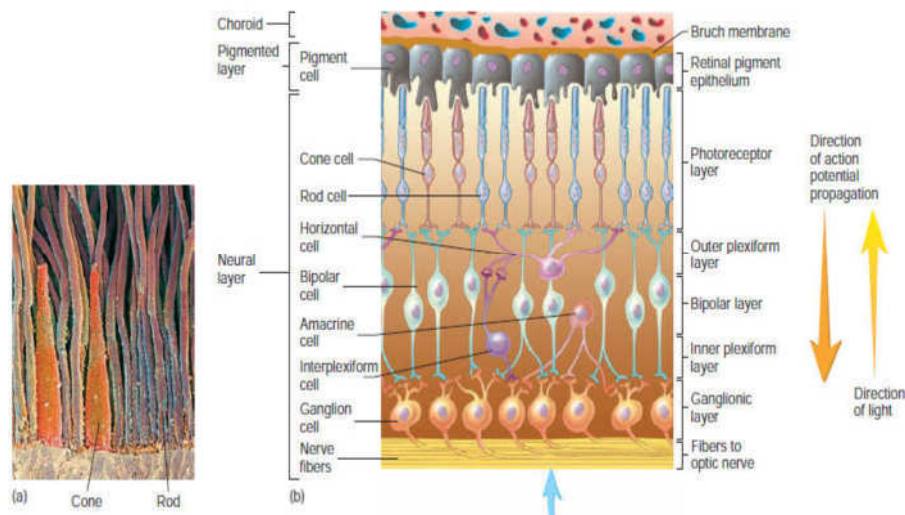
As an object is brought closer and closer to the eye, accommodation becomes more and more difficult because the lens cannot become any more convex. At some point, the eye no longer can focus the object, and it is seen as a blur. The point at which this blurring occurs is called the **near point of vision**, which is usually about two to three inches from the eye for children, four to six inches for a young adult, 20 inches for a 45-year-old adult, and 60 inches for an 80-year-old adult. This increase in the near point of vision is called **presbyopia**. It occurs because the lens becomes more rigid with increasing age, which is why some older people say they could read with no problem if they only had longer arms.

2. *Pupil constriction.* When we look at a close-up object, the pupil diameter decreases, which increases the depth of focus. The **depth of focus** is the greatest distances through which an object can be moved and still remain in focus on the retina. The main factor affecting depth of focus is the size of the pupil. If the pupillary diameter is small, the depth of focus is greater than if the pupillary diameter is large. With a smaller pupillary opening, an object may therefore be moved slightly nearer or farther from the eye without disturbing its focus. This is particularly important when viewing an object at close range because the interest in detail is much greater, and therefore the acceptable margin for error is smaller. When the pupil is constricted, the light entering the eye tends to pass more nearly through the center of the lens and is more accurately focused than light passing through the edges of the lens. Pupillary diameter also regulates the amount of light entering the eye. The smaller the pupil diameter, the less light entering the eye. As the pupil constricts during close vision, therefore, more light is required on the object being observed.
  
3. *Convergence.* Because the light rays entering the eyes from a distant object are nearly parallel, both pupils can pick up the light rays when the eyes are directed more or less straight ahead. As an object moves closer, however, the eyes must be rotated medially so that the object is kept focused on corresponding areas of each retina. Otherwise, the object appears blurry. This medial rotation of the eyes is accomplished by a reflex that stimulates the medial rectus muscle of each eye. This movement of the eyes is called convergence.

## Structure and Function of the Retina

The retina consists of an inner, neural layer and an outer, pigmented layer. The **neural layer** contains three layers of neurons: photoreceptor, bipolar, and ganglionic. The photoreceptor layer contains **rods** and **cones**, which are the photoreceptor cells that respond to light. The rods and cones synapse with **bipolar cells**, which in turn synapse with **ganglion cells**. Axons from the ganglion cells pass over the inner surface of the retina, converge at the optic disc (blind spot), and exit the eye as the optic nerve (CN II). The neural layers are separated by the plexiform (like a braid) layers. The outer plexiform layer is where the photoreceptor cells synapse with the bipolar cells and the inner plexiform layer is where the bipolar cells synapse with the ganglion cells.

The **pigmented layer** consists of **retinal pigment epithelium (RPE)**, a single layer of cuboidal epithelial cells filled with melanin. It rests on the **Bruch membrane**, which is the inner layer of the choroid consisting of collagen and elastic fibers. Cells of the RPE phagocytize the spent tips of rods and cones and produce retinal from vitamin A. Along with the choroid, the pigmented layer provides a black-brown matrix that enhances visual acuity by isolating individual photoreceptors and reducing light scattering.



**Fig. 4.4: Retina**

### Rods

Rods are responsible for non - colour vision and vision under conditions of reduced light. Even though rods are very sensitive to light, they

cannot detect colour, and sensory input reaching the brain from rods is interpreted by the brain as shades of gray. Rods are bipolar neurons with modified, light-sensitive dendrites, which are cylindrical in shape.

## **Cones**

Cones are responsible for colour vision and visual acuity. Colour is a function of the wavelength of light, and each colour results from a certain wavelength of visible light. Cones require relatively bright light to function. As the light decreases, so does the colour of objects that can be seen until, under conditions of very low illumination, the objects appear gray. This occurs because, as the light decreases, the number of cones responding to the light decreases but the number of rods increases. Cones are bipolar photoreceptor cells with a conical, light-sensitive part that tapers slightly from base to apex.

## **Distribution of Rods and Cones in the Retina**

Each eye has approximately 120 million rods and six to seven million cones. The cones are most concentrated in the fovea centralis and the macula. The fovea centralis has approximately 35,000 cones and no rods. The rest of the macula has more cones than rods. Cones are involved in visual acuity, in addition to their role in colour vision. When one is looking at an object directly in front of the eye, the focusing system of the eye places the image on the macula and fovea centralis. The high concentration of cones makes it possible to see fine details.

The rods are 10–20 times more plentiful than cones over most of the retina away from the macula. The high number of rods enables them to “collect” light, and they are more important in low-light conditions.

## **Inner Layers of the Retina**

Within the inner layers of the retina, interneurons modify the signals from the photoreceptor cells before the signal leaves the retina.

**Horizontal cells** in the outer plexiform layer synapse with photoreceptor cells and bipolar cells. **Amacrine cells** in the inner plexiform layer synapse with bipolar and ganglion cells. **Interplexiform cells** connect cells in the outer and inner plexiform layers, forming feedback loops. The interneurons are either excitatory or inhibitory on the cells with which they synapse. By increasing the signal from some photoreceptors and decreasing the signal from others, these interneurons increase the differences between boundaries, such as the edge of a dark object against a light background.

### 3.3 Visual Pathway

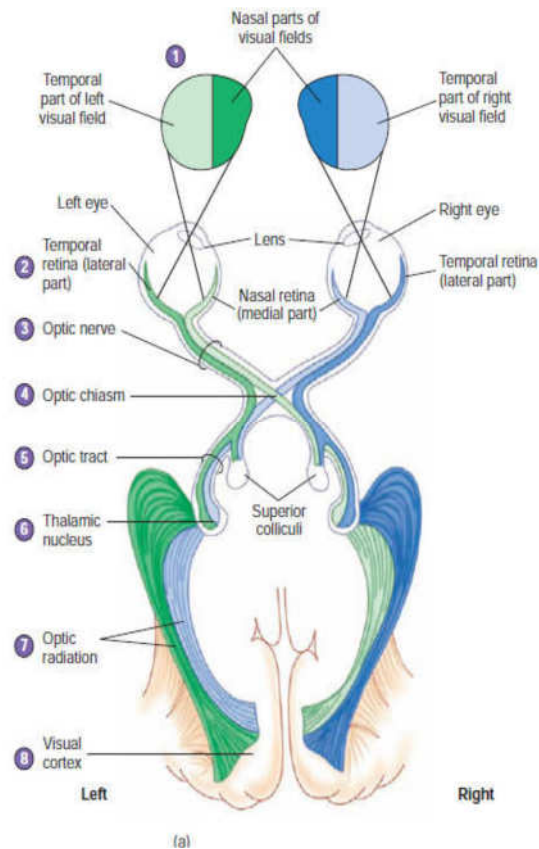
The optic nerve (II) leaves the eye and exits the orbit through the optic foramen to enter the cranial cavity. Just anterior to the pituitary gland, the optic nerves are connected to each other at the **optic chiasm**. Ganglion cell axons from the nasal (medial) retina cross through the optic chiasm and project to the opposite side of the brain. Ganglion cell axons from the temporal (lateral) retina pass through the optic chiasm and project to the brain on the same side of the body without crossing.

Beyond the optic chiasm, the axons form the **optic tracts**. Most of the optic tract axons terminate in the thalamus. Some axons do not terminate in the thalamus but separate from the optic tracts to terminate in the **superior colliculi**, the center for visual reflexes. Neurons from the thalamus form the fibers of the **optic radiations**, which project to the **visual cortex** in the occipital lobe. Neurons of the visual cortex integrate the messages coming from the retina into a single message, translate that message into a mental image, and then transfer the image to other parts of the brain, where it is evaluated and either ignored or acted on.

The image seen by each eye is the **visual field** of that eye. The visual field of each eye can be divided into temporal (lateral) and nasal (medial) parts. The temporal part of a visual field projects onto the nasal retina, which projects to the visual cortex on the opposite side of the brain. The nasal part of a visual field projects onto the temporal retina, which projects to the same side of the brain. The nerve pathways are arranged in such a way that images entering the eye from the right part of each visual field (right temporal and left nasal) project to the left side of the brain. Conversely, the left part of each visual field (left temporal and right nasal) projects to the right side of the brain.

## The visual pathway

1. Each visual field is divided into temporal and nasal parts.
2. After passing through the lens, light from each part of a visual field projects to the opposite side of the retina.
3. An optic nerve consists of axons extending from the retina to the optic chiasm.
4. In the optic chiasm, axons from the nasal part of the retina cross and project to the opposite side of the brain. Axons from the temporal part of the retina do not cross.
5. An optic tract consists of axons that have passed through the optic chiasm (with or without crossing) to the thalamus.
6. The axons synapse in thalamic nuclei. Collateral branches of the axons in the optic tracts synapse in the superior colliculi.
7. An optic radiation consists of axons from thalamic neurons that project to the visual cortex in the occipital lobe.
8. The right part of each visual field (*dark green and light blue*) projects to the left side of the brain, and the left part of each visual field (*light green and dark blue*) projects to the right side of the brain.



**Fig.4.5: The Visual Pathway**

### 3.4 Clinical Correlates

1. **Myopia** or **short - sightedness**, is the ability to see close objects clearly while distant objects appear blurry. Myopia is a defect of the eye in which the focusing system, the cornea and lens, is optically too powerful, or the eyeball is too long. As a result, images are focused in front of the retina. Myopia is corrected by a concave lens that spreads out the light rays coming to the eye so that, when the light is focused by the eye, it is focused on the retina. Such lenses are called “minus” lenses.
2. **Hypermetropia** or long – sightedness is the ability to see distant objects clearly while close objects appear blurry. Hypermetropia is a disorder in which the cornea and lens system is optically too weak or the eyeball is too short. As a result, the focused image is “behind” the retina when looking at a close object. In hypermetropia, the lens must accommodate to bring somewhat distant objects into focus, which would not be necessary for a normal eye. Closer objects cannot be brought into focus because the lens cannot change shape enough to focus the image on the retina. Hypermetropia is corrected by a convex lens that causes

light rays to converge as they approach the eye and to focus on the retina. Such lenses are called “plus” lenses.

3. **Presbyopia** is the normal, presently unavoidable degeneration of the accommodation power of the eye that occurs as a consequence of aging. It occurs because the lens becomes hard and less flexible. The average age for onset of presbyopia is the mid-forties. Avid readers and people engaged in fine, close work may develop the symptoms earlier. Presbyopia can be corrected by the use of “reading glasses” which are worn only for close work and are removed when the person wants to see at a distance. Alternatively, the problem may be corrected by the use of **bifocals**, which have a different lens in the top and the bottom, or by **progressive lenses**, in which the lens is graded.
4. **Astigmatism** This is a defect in which the cornea or lens is not uniformly curved and the image is not sharply focused. Glasses may be made to adjust for the abnormal curvature as long as the curvature is not too irregular. If the curvature of the cornea or lens is too irregular, the condition is difficult to correct.
5. **Night Blindness** Everyone sees less clearly in the dark than in the light. A person with night blindness, or nyctalopia, however, may not see well enough in a dimly lit environment to function adequately. Night blindness results from loss of rod function. It can result from general retinal degeneration, such as occurs in retinitis pigmentosa or detached retinas. Temporary night blindness can result from a vitamin A deficiency because vitamin A is necessary to produce retinal. Patients with night blindness can be helped with electronic optical devices, including monocular pocket scopes and binocular goggles that electronically amplify light.
6. **Glaucoma** Glaucoma is a condition involving excessive pressure build-up in the aqueous humour. Glaucoma results from an interference with normal reentry of aqueous humour into the blood or from an overproduction of aqueous humour. The increased pressure within the eye can close off the blood vessels entering the eye and may destroy the retina or optic nerve, resulting in blindness. Everyone older than 40 years should be checked every two to three years for glaucoma; those older than 40 who have relatives with glaucoma should have an annual check-up. Glaucoma is usually treated with eye drops, which do not cure the problem but keep it from advancing. In some cases, laser or conventional surgery may be used.

### Self-Assessment Exercises

- describe the anatomy of the eye
- describe the focusing system of the eye and how it adjusts to see distant and near objects
- explain the structure of the retina, and how light entering the eye results in action potentials in the optic nerve

## 4.0 CONCLUSION

You learnt that the visual system includes the eyes, the accessory structures, and the sensory neurons that project to the cerebral cortex where action potentials conveying visual information are interpreted.

## 5.0 SUMMARY

- The fibrous layer is the outer layer of the eyeball. It consists of the sclera and cornea. The sclera is the posterior four-fifths of the eyeball. It is white connective tissue that maintains the shape of the eyeball and provides a site for muscle attachment. The cornea is the anterior one-fifth of the eye. It is transparent and refracts light that enters the eye.
- The vascular layer is the middle layer of the eyeball. The black choroid prevents the reflection of light inside the eye. The iris is smooth muscle regulated by the autonomic nervous system. It controls the amount of light entering the pupil. The ciliary muscles control the shape of the lens. The ciliary process produces aqueous humour.
- The retina is the inner layer of the eyeball and contains neurons sensitive to light. The macula (fovea centralis) is the area of greatest sensitivity to light. The optic disc is the location through which nerves exit and blood vessels enter the eye. It has no photosensory cells and is therefore the blind spot of the eye.
- The eyeball has three chambers: anterior, posterior, and vitreous. The anterior and posterior chambers are filled with aqueous humour, which circulates and leaves by way of the scleral venous sinus. The vitreous chamber is filled with vitreous humour.
- Accessory structures of the eye are the eyebrows, the eyelids, the conjunctiva and lacrimal glands.
- Visual pathway comprises ganglion cell axons from the optic nerve, optic chiasm, and optic tracts. They extend to the



thalamus, where they synapse. From there, neurons form the optic radiations that project to the visual cortex.

## 6.0 TUTOR MARKED ASSIGNMENT

1. Tears
  - a. are released onto the surface of the eye near the medial corner of the eye.
  - b. in excess are removed by the scleral venous sinus.
  - c. in excess can cause a sty.
  - d. can pass through the nasolacrimal duct into the oral cavity.
  - e. contain water, salts, mucus, and lysozyme.
  
2. The fibrous layer of the eye includes the
  - a. conjunctiva.
  - b. sclera.
  - c. choroid.
  - d. iris.
  - e. retina.
  
3. Concerning axons in the optic nerve from the right eye,
  - a. they all go to the right occipital lobe.
  - b. they all go to the left occipital lobe.
  - c. they all go to the thalamus.
  - d. they all go to the superior colliculus.
  - e. some go to the right occipital lobe and some go to the left occipital lobe.
  
4. Contraction of the smooth muscle in the ciliary body causes the
  - a. lens to flatten.
  - b. lens to become more spherical.
  - c. pupil to constrict.
  - d. pupil to dilate.
  
5. Given these events:
  1. medial rectus contracts
  2. lateral rectus contracts
  3. pupils dilate
  4. pupils constrict
  5. lens of the eye flattens
  6. lens of the eye becomes more spherical

Assume you are looking at an object 30 feet away. If you suddenly look at an object that is one (1) foot away, which events occur?

- a. 1,3,6
- b. 1,4,5
- c. 1,4,6
- d. 2,3,6
- e. 2,4,5
6. Why do you get a “runny nose” when you cry?
7. What are the layers of the retina?
8. Which are more numerous, rods or cones?

## **7.0 REFERENCES/FURTHER READING**

Hutchinson, M., Mallat, J., Marieb, E.N., Wilhelm P.B. (2007). A Brief Atlas of the Human Body. Sna Franciscio: Pearson Education Inc.

Katherine M. A. Rogers and William N. Scott (2011) Nurses! Test Yourself in Anatomy and Physiology

Kathryn A. Booth, Terri. D. Wyman (2008) Anatomy, Physiology, and Pathophysiology for Allied Health

Keith L Moore, Persuade T.V.N (2018), The Developing Human Clinically Oriented Embryology 11th Edition Lippincott Williams & Wilkins

Kent M. Van De Graff, R.Ward Rhees, Sidney Palmer (2010) Schaum’s Outline of human Anatomy and Physiology 3rd edition.

Philip Tate (2012) Seeley’s Principles of Anatomy & Physiology 2nd ed.

Sadler T.W (2012), Langman’s Medical Embryology 12th edition.

Seeley’s Principles of Anatomy & Physiology, Second edition Published by McGraw-Hill, a business unit of The McGraw-Hill Companies, Inc., 1221 Avenue of the Americas, New York, NY 10020. Copyright c 2012- Chapter 17&18

## **MODULE 2      CENTRAL NERVOUS SYSTEM**

### **CONTENTS**

|        |  |
|--------|--|
| Unit 1 | Embryology of the central nervous system |
| Unit 2 | Spinal cord                              |
| Unit 3 | Brain stem                               |
| Unit 4 | Diencephalon and Basal ganglia           |
| Unit 5 | Cerebral hemisphere                      |
| Unit 6 | Ventricles and cerebrospinal fluid       |
| Unit 7 | Blood supply of central nervous system   |

### **1.0 INTRODUCTION**

During a picnic on a sunny spring day, it is easy to concentrate on the delicious food and the pleasant surroundings. The maintenance of homeostasis requires no conscious thought. The autonomic nervous system (ANS) helps keep body temperature at a constant level by controlling the activity of sweat glands and the amount of blood flowing through the skin. The central nervous system (CNS) consists of the brain and spinal cord, the peripheral nervous system (PNS) consists of sensory receptors and nerves outside the CNS. The PNS includes 12 pairs of cranial nerves and 31 pairs of spinal nerves. The CNS receives sensory information, integrates and evaluates that information, stores some information, and initiates reactions.

### **2.0 OBJECTIVES**

At the end of this module, you should be able to:

- discuss the formation of the brain and the spinal cord from the most primitive neural tube
- discuss the anatomy of the central nervous system.

## **UNIT 1      EMBRYOLOGY OF THE CENTRAL NERVOUS SYSTEM**

### **CONTENTS**

|     |                          |
|-----|--------------------------|
| 1.0 | Introduction             |
| 2.0 | Objectives               |
| 3.0 | Main Content             |
|     | 3.1 Anomalies of closure |
|     | 3.2 Spinal cord          |
| 4.0 | Conclusion               |
| 5.0 | Summary                  |

- 6.0 Tutor-Marked Assignment
- 7.0 References/Further Reading

## 1.0 INTRODUCTION

Brain development occurs at several stages during childhood. The critical period for brain growth appears to be during the first sixteen weeks of life. At birth, a baby's brain weighs approximately 25 per cent of its future adult weight. By the time the child is two years old the brain has increased to 75 per cent, and by six years, 90 per cent of its eventual weight. This, then, indicates phenomenal growth of the central nervous system during the early years. Peripheral nerves continue to become myelinated (grow fatty sheaths to increase nerve transmission rate) and fine physical control appears as the child moves towards adult status.

With the unique environment impinging on every waking and sleeping hour, this plastic nervous system constantly matures and changes as demands are put upon it.

## 2.0 OBJECTIVES

At the end of this unit, you will be able to:

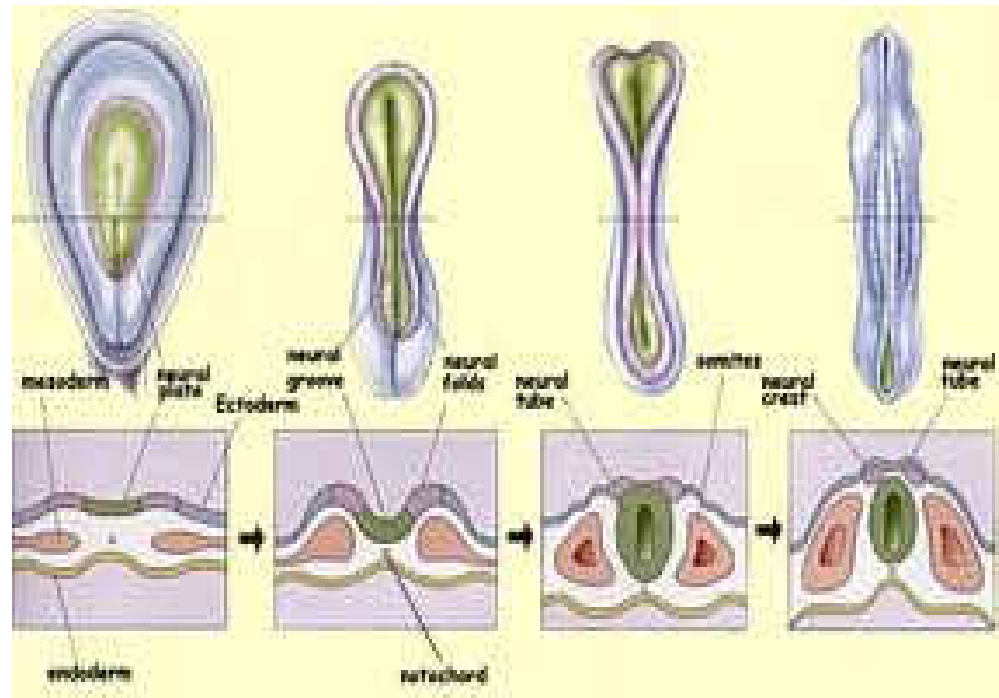
- describe the transformation of the neural tube into the different parts of the definitive brain.
- differentiate between the events that lead to the formation of the brain and the spinal cord.
- discuss the cellular formation, differentiation and migration, and the role of such processes in the formation of the brain and spinal cord.

## 3.1 Anomalies of closure

The CNS is an ectodermal derivative that begins to differentiate in the 3rd intrauterine week in humans.

The brain starts its development soon after conception; it is vulnerable to damage through pregnancy. The first indication of the nervous system is within the neural plate, a thickened area of the ectoderm that forms after the ovum has been fertilised in the third week of gestation. Slippers shaped neural plate thickens rostral to the primitive node and midline depression in the neural plate forms the neural groove. Edges of the neural groove rise on both sides of the midline, fusing to convert the groove to a tube. This neural tube is the beginning of the brain and spinal cord. As the neural tube separates from the surface ectoderm cells, the neural folds form the neural crest. Ganglia of the spine, cranial

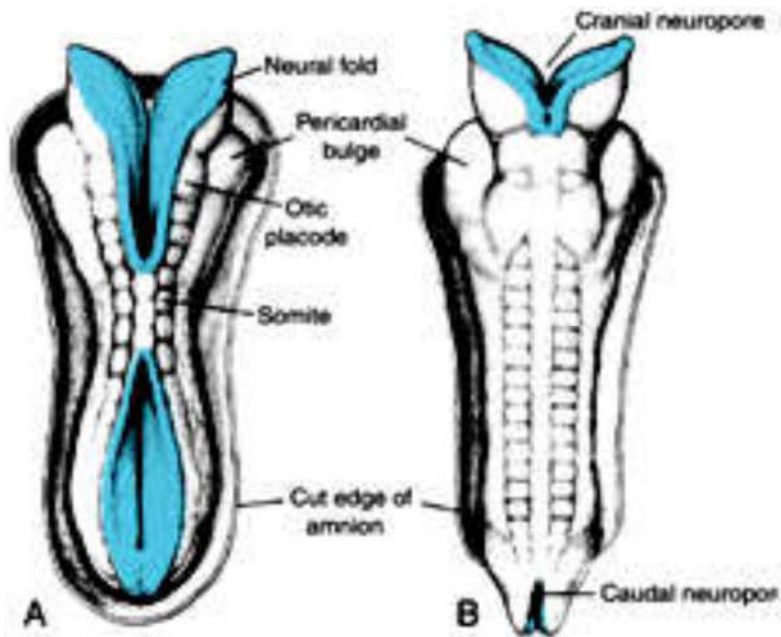
and autonomic nervous system develop from the neural crest. Fusion of the neural groove edges begin in the cervical region and proceed in cephalocaudal directions.



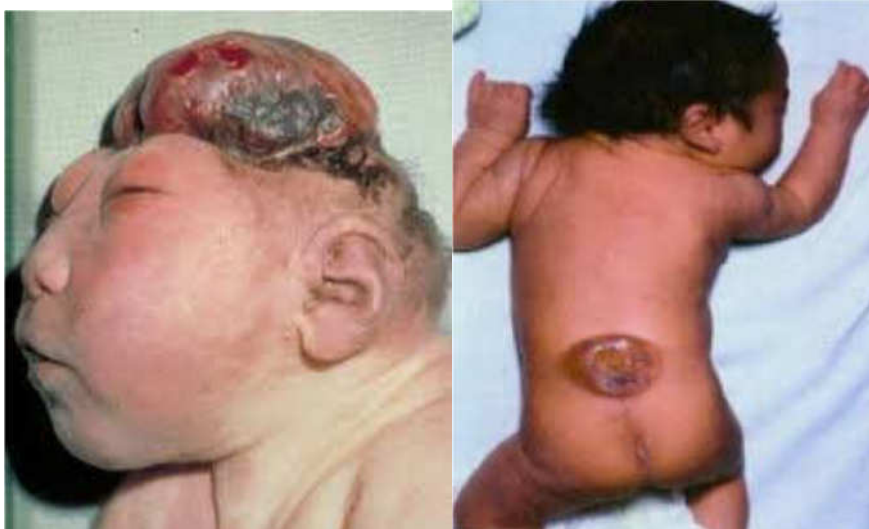Formation of the neural tube.

A more cranial site of closure is noted in the forebrain to close the cranial neuropore in conjunction with the cervical closure site on the 25th intrauterine day. Caudal neuropore closes in similar fashion 2 days after the cranial counterpart. The neural tube give rise to the brain and spinal cord, the canal of the tube differentiates into the ventricles and the central canal of the spinal cord.

The embryo at twenty-three days shows the hindbrain and midbrain to be formed, and the neural tube closes. In the fourth week the head folds begin to develop as the forebrain grows rapidly. In the fifth week the eye starts to grow, and cerebral hemispheres also develop from this area. The nerves of the branchial arches become the cranial nerves. Peak head breadth growth velocity occurs at thirteen post-menstrual weeks, although a relatively high velocity continues to about thirty weeks. Peak head circumference velocity occurs two to three weeks later, because the cerebellum situated at the back of the skull grows later than the cerebrum. Head volume, representing brain size, has its peak velocity at thirty weeks and growth rapidly slows after this.



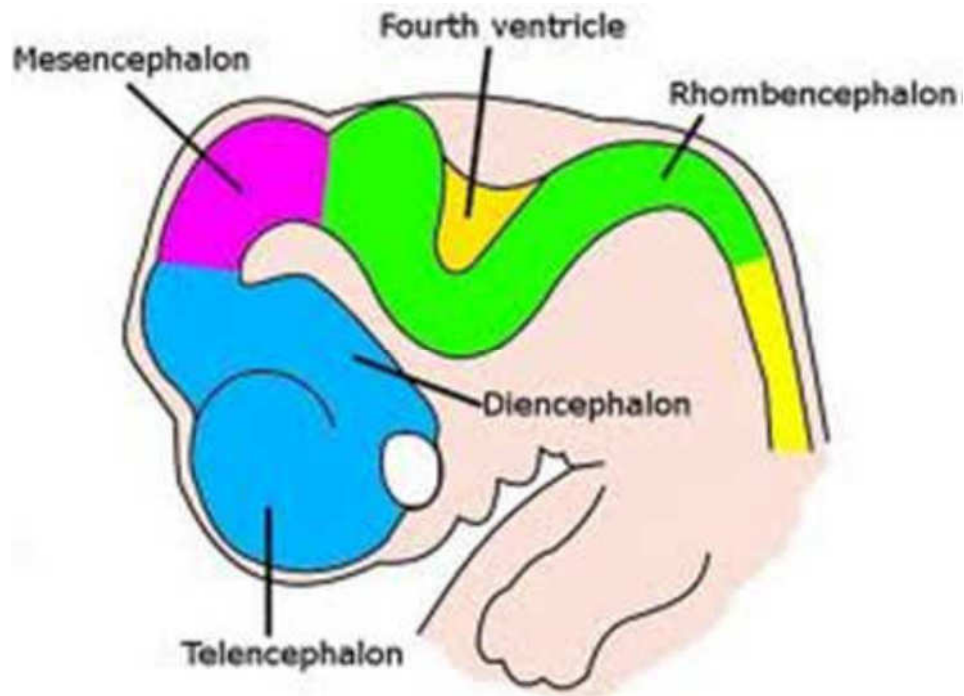
Anomalies of the closure of the neural tube results in several clinical conditions such as anencephaly and spinal bifida. Various degrees of these anomalies noted in many regions of the world. The introduction of folic acid supplementation in ante-natal care had drastically reduced the occurrence of such anomalies.



Anencephaly

Spina bifida

### 3.1.3 Brain Vesicle Formation

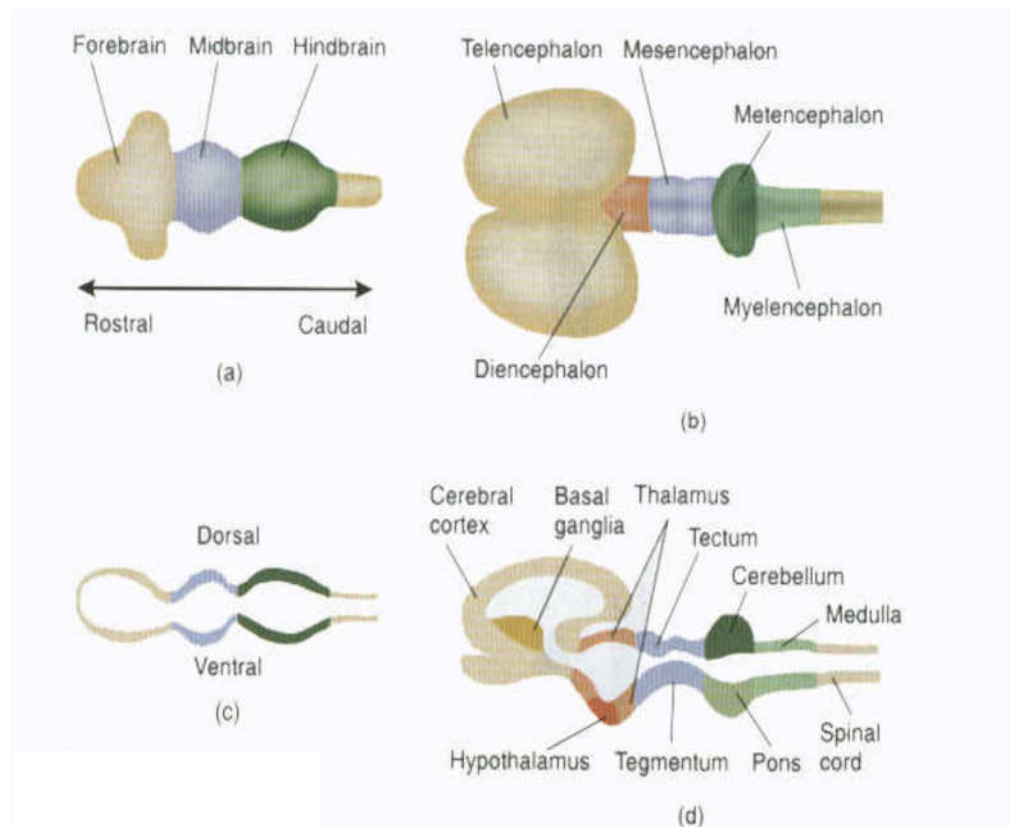


The 4th week witnesses the differentiation of the cranial part of the neural tube into the 3 brain vesicles. Boundary demarcation follows differential growth rate leading to the formation of the prosencephalon, mesencephalon and rhombencephalon cranio-caudally. Same mechanism results in the formation of 2 flexures, cervical and cephalic flexures. Cephalic flexure opens to the ventral surface while the cervical opens to the dorsal surface.

By the 5th week of development, the Prosencephalon is divided into the Telencephalon and Diencephalon by differential growth rate. The Rhombencephalon also divides into the cranial Metencephalon and caudal Myelencephalon roughly by the cephalic (Pontine) flexure. The canal of the neural tube follows the differentiation leading to formation of Lateral, 3rd, 4th ventricles and the Aqueduct of Sylvius.

#### Telencephalon

The prosencephalon undergoes massive growth in the 5th week. Growth is more in the cranio-lateral portion as against the midline portion. The differential growth rate results in the ballooning of the lateral portion forming the telencephalon while the more quiescent midline portion forms the diencephalon. Ballooning is more in the dorsal part of the telencephalon, the ventral part consist largely of the corpus striatum. The roof plate ependymal layers in addition to surrounding vascular mesenchyme form the choroid plexus.



The choroid plexus bearing portion get “invaginated” due to the lateral expansion of the ballooning lateral wall.

Just beyond the choroid plexus bearing region, there is proliferation of neuroblast resulting in the slightly thickened portion that forms the Hippocampus. The hippocampal portion get “buried” within the enlarging cortex alongside the roof portion. It bulges into the cavity of the lateral ventricle. The enlarging dorsal portion of the telencephalon forms the cerebral cortex. Expansion is in the anterior, posterior and lateral directions forming the frontal, occipital and temporal lobes respectively. The ballooned cerebral cortex envelops the diencephalon, mesencephalon and upper part of metencephalon.

Axons from the cortical neurons coalesce and pass through the corpus striatum dividing it into the medial caudate nucleus and the lateral lentiform nucleus. The dividing axonal bundle forms the internal capsule.

In the latter quarter of gestation, expansion of the cerebral cortex exceeds the capacity of the cranial vault resulting in convolutions.

The degree of convolutions is directly related to the degree of behavioural and neuronal complexity.



## Diencephalon

The portion of the prosencephalon just caudal and medial to the telencephalon. It consists of roof plate and 2 alar plate, basal plate and floor plate are absent. The roof plate consists of ependymal lining which forms the choroid plexus with the surrounding vascular mesenchyme.

There is a caudal neuroepithelial thickening on the dorsal surface which evaginates around the 7th week to form the pineal body sitting on the mesencephalon.

The alar plate witness aggregation of cells which is divided into a dorsal thalamus and a ventral hypothalamus by a hypothalamic sulcus. Cells of the thalamus proliferate very rapidly resulting in an inward bulge of the Thalamus obliterating the cavity and forming an adhesion. A ventral thickening of the neuro-epithelium results in the formation of the mammillary body which is functionally related to the hypothalamus. An extension of the ventral wall forms the infundibulum. The infundibulum alongside the Rathke's pouch (from the oral cavity) form the pituitary gland sitting in the Sella Turcica. The cephalic flexure topographically makes the connection possible.

## Mesencephalon

It has the typical basal and alar portions, the basal (ventral) part mediate motor functions while the alar (dorsal) part mediates sensory function. The sulcus limitans forms the boundary between the 2 sides. The basal plate contains 2 groups of motor cells that aggregate into nuclei viz;

**Somatic efferent;** medially placed CN3 and CN4 motor supply to the extraocular muscles.

**General visceral efferent;** laterally placed nucleus of Edinger-Westphal (sphincter pupillary muscle).

Fibers that connect the spinal cord through the pons from the cerebral cortex pass through the marginal layer over the basal layer. Marginal layer over the basal layer enlarges to accommodate fibers forming the crus cerebri. No particular nucleus is formed in the alar plate of the mesencephalon. The overlying marginal layer of the alar plate had neuroblast wave in it resulting in its enlargement. Initially 2 longitudinal elevation is noticed in the marginal layer of the alar plate, with further development, a transverse furrow separates them. 4 colliculi are thus formed namely the inferior and superior colliculi on both sides of the median sulcus. Serve as synaptic relay centre for auditory and visual impulses respectively.

## **Metencephalon**

It is the cranial portion of the Rhombencephalon. It has well defined basal and alar plate in which neuroblasts form cellular aggregates that form nuclei. The roof plate consists largely of ependymal layer, opened alar plate. It is also the point of formation of the pons and cerebellum.

The fibres from the cerebral cortex to the spinal cord pass through the marginal layer that overlies the basal plate. Passage of the fibres result in the enlargement of the marginal layer forming the Pons. In addition to the fibres, pontine nuclei that are formed from the alar region of the rhombencephalon migrate in the marginal layer into the Pons. The basal plate neuroblast differentiate into neurons that are arranged into 3 motor nuclei mediolaterally;

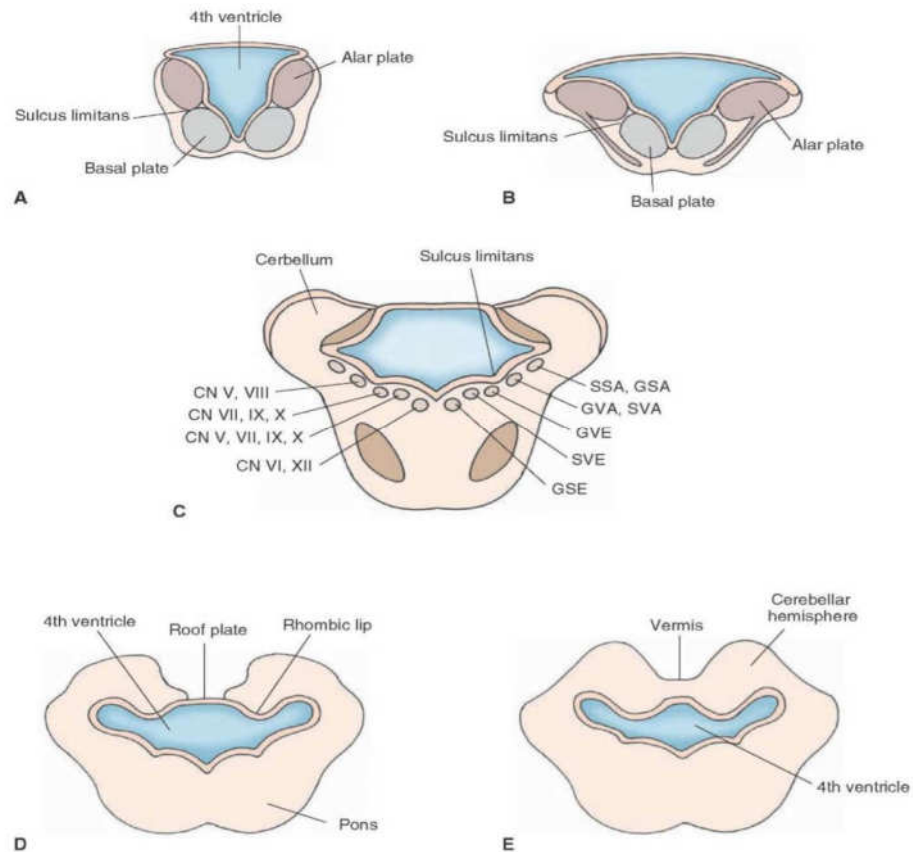
**Somatic efferent;** CN6 for extraocular mm,

**Special visceral efferent;** CN5, CN7 for the 1st and 2nd pharyngeal arches.

**General visceral efferent;** CN9 secretomotor supply submandibular and sublingual glands

The alar plate of the metencephalon contains 3 groups of nuclei that subserve sensory modalities;

**Somatic afferent;** CN5, CN8 complex



The dorsolateral part of the marginal layer over the alar plate differentiates into the Rhombic lip.

The rhombic lip is wide apart caudally but closes cranially. Pontine flexure ensures the folding of the metencephalon on itself while the rhombic lip differentiates into the cerebellar plates. At 12 weeks, a central vermis and 2 lateral dilated cerebellar hemisphere are identified. A transverse fissure separates the cerebellar plate into an upper and lower parts. The fissure separate the vermis from the Nodule while the hemisphere is separated from the Flocculus. The developing cerebellum consist of 3 layers viz; neuroepithelial, mantle and marginal. The external granular layer differentiates from the neuroepithelial layer. The EGL give rise to granule, purkinje, golgi II neuron cells by the 6<sup>th</sup> month, while the other cells (basket and stellate) are derived from the marginal layer

### Myelencephalon

This is the caudal portion of the rhombencephalon. The dorso-lateral wall is opened up, basal and alar plate are still identifiable separated by the sulcus limitans. 3 set of motor nuclei are identified in the basal plate;

**Somatic efferent;** forms a motor column continuous cranio-caudally, CN12, (tongue) CN6, CN4, CN3 (eye) at different levels.

**Special visceral efferent;** continues cranially as a motor column CN11, CN10, CN9 supplying the striated muscles of the soft palate and larynx, pharynx, heart and gut.

**General visceral efferent;** supply the involuntary muscle of the gut, heart and respiratory system.

The alar plate have similar arrangement;

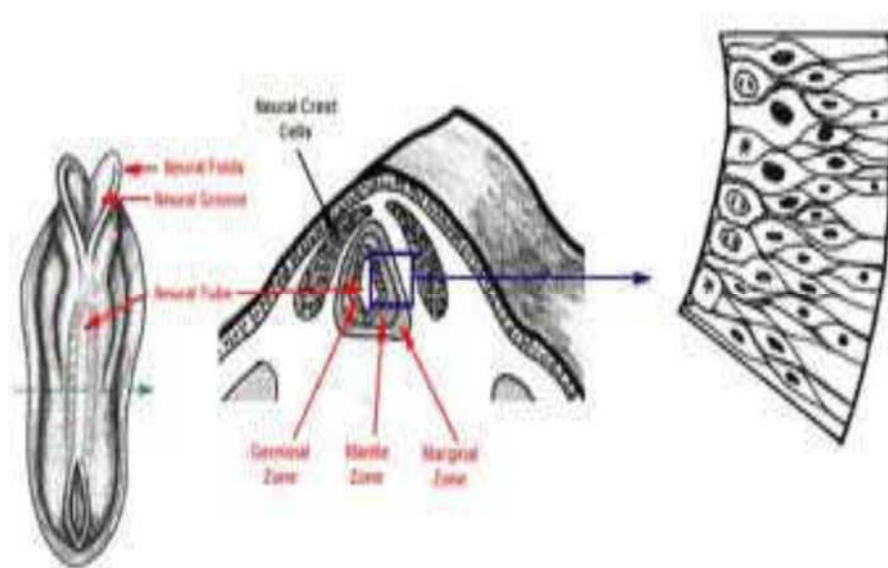
**Somatic afferent;** CN8, CN5 for the ear and head surface.

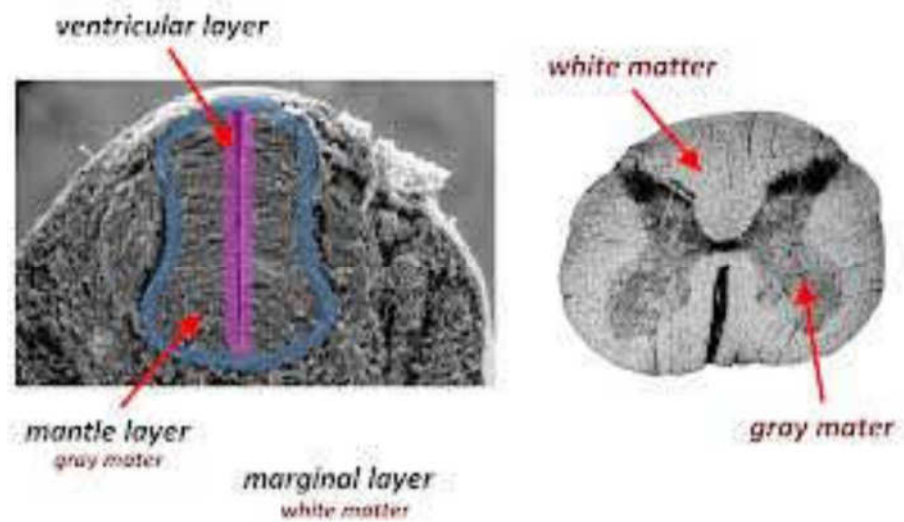
**Special visceral afferent;** CN9 for the tongue taste bud. The ependymal lining of the roof plate alongside the vascular mesenchyme form the choroid plexus that produces CSF.

## NEUROEPITHELIAL CELLS

The neuroepithelial cells lining the neural tube are of simple columnar type.

Increase cellular proliferation after closure of tube, giving rise to neuroblast (large deeply stained nucleus and pale cytoplasm). The neuroblast gives rise to the 2nd layer, mantle layer which differentiate into the gray matter. The axons of the mantle layer neurons coalesce in the 3rd layer (outermost) forming the marginal layer.

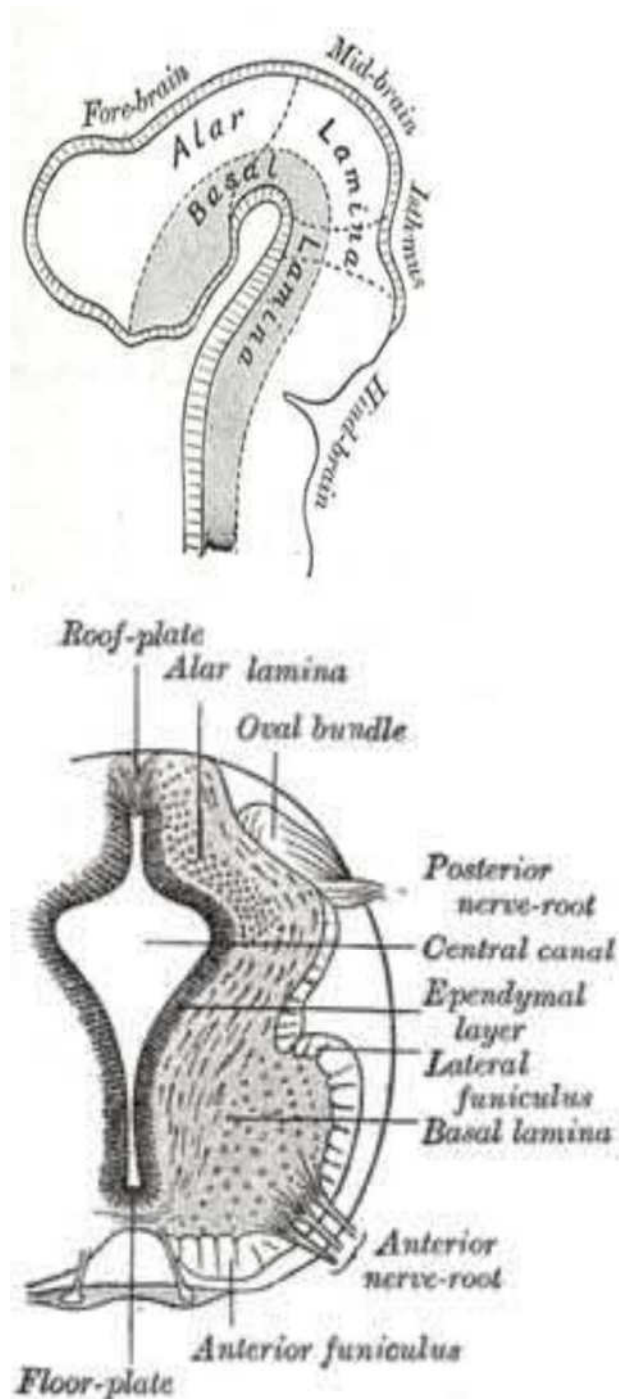




The mantle layer differentiates into a basal and alar plate.

The roof and floor plate are usually devoid of neuroblast, have only the ependymal layer.

The ependymal layer is the final derivative of the neuroepithelial layer. The dorsal Alar plate houses neurons that subserve sensory modalities, while the ventral basal plate houses neurons that subserve motor modalities.



## NEUROHISTOLOGY

Neuroblast; derived from neuroepithelial cell, differentiate through uni, bi to multipolar neurons. Neurons may take different shapes and size depending on function.

Glial cell; produced by the neuroepithelial cells following the production of neurons. Differentiate into astrocyte in the mantle layer and oligodendrocyte in the marginal layer.

Astrocytes are star shaped, mainly protoplasmic in the mantle layer and fibrous in the marginal layer. It is important for the formation of the blood brain barrier.

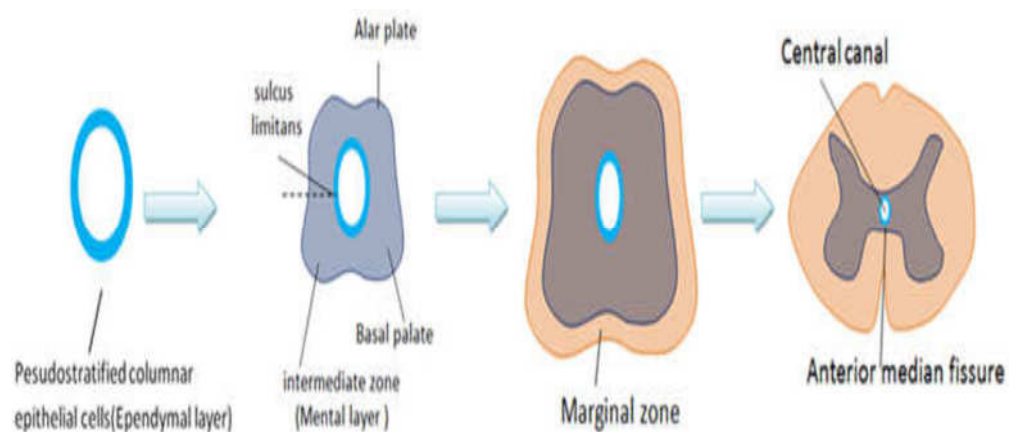
Oligodendrocytes have small round deeply stained nucleus usually with a halo in routine stain, appear in pair or string like formation. It is responsible for myelination in the central nervous system. Myelination of the white matter begins in the 2nd trimester and continues postnatally.

Microglia are of mesenchymal origin, invade the CNS in the latter half of gestation. Usually cigar shaped with fine processes. They are phagocytic cells

Ependymal cells are the final derivative of neuroepithelial cells. They line the ventricle and central canal. They are cuboidal and low columnar in shape.

### 3.2 Spinal Cord

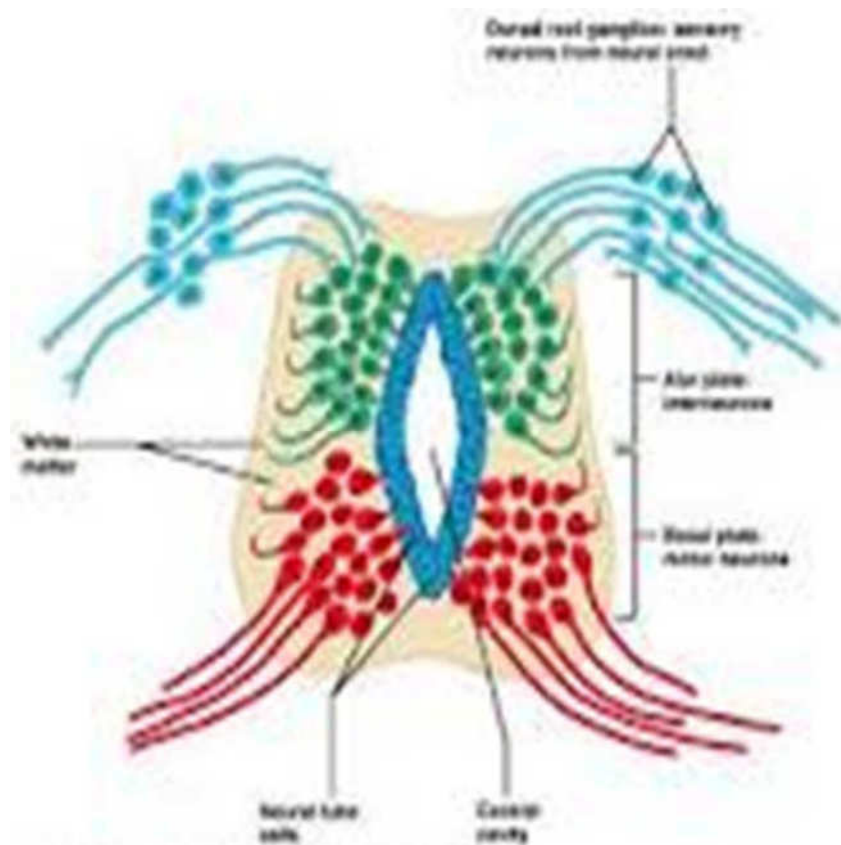
The mantle layer gives rise to the gray matter of the spinal cord, while the marginal layer forms the white matter of the spinal cord. Ventral basal plate subserves motor function while dorsal alar plate subserves sensory functions. Neuroblast aggregation in between the basal and alar plate for the intermediate horn in some part of the developing spinal cord. Intermediate horn neuroblast differentiates into the neurons of the sympathetic portion of the autonomic nervous system. Intermediate horn is limited to the region of T1 to T12 and L2-L3.



The axons of the basal plate neuron coalesce exiting through the marginal layer to form the ventral motor root of the corresponding spinal nerve about the 4th week. Dorsal root ganglia are derivatives of the neural crest cells, its neuroblast differentiate into bipolar neurons.

The medial process enters the marginal layer of the alar plate of the SC ending in the dorsal horn or ascending to higher centers. The other

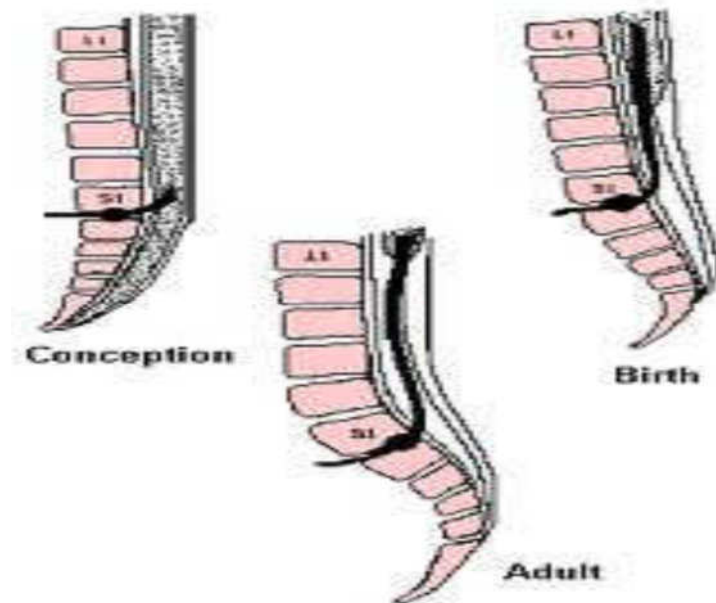
process that grows peripherally coalesces with the ventral motor root to form the spinal nerve trunk. Myelination is a function of the Schwann cells in the axons outside the SC while the portion within the SC is myelinated by oligodendrocyte.



The rate of elongation of the spinal cord and the vertebral column is not the same. The vertebral column outpaces the spinal cord resulting in an apparent ascent of the developing spinal cord. At about 3rd month of life, spinal cord extends the entire length of the vertebral column, at birth spinal cord ends at the lower border of L3 while at adult hood it ends at



L2/L3 boundary. Implication is the obliquity of spinal nerve forming cauda equine and the formation of filum terminale.



## NEURONAL MIGRATION

The neuroblast of the cerebral cortex proliferates rapidly around the ventricle, forming neurons and supporting (glia) cells. The glial cells differentiate into the oligodendrocyte and astrocyte.

The neurons that are formed from the neuroblast are largely of 2 types; viz granular (sensory cortex) and pyramidal (motor). Different sizes and composition of neurons at each point confer a stratified arrangement on the cerebral cortex. Each layer consists of neurons of specified composition and subserves similar functions. Movement of forming neurons from the point of neuroblast proliferation to their definitive position is mediated by internal and external cues.

Mechanism of migration is either radial or tangential means. While radial migration means is mainly employed by the granular and pyramidal neurons, the tangential mean is employed by interneurons. Settling of the neuron in their definitive position is in an inside-out fashion. Migration results in 6-layered cortical arrangement.

- Molecular; few oligodendrocyte almost no neuron.
- External granular; more of round granular neurons.
- External pyramidal; contains small pyramidal neurons.
- Internal granular; contain granular cells that are closely packed.

- Internal pyramidal; contain medium to large pyramidal cells, home to Betz cells.
- Multiform layer; contains different cell type.

### **Clinical correlates**

**Anencephaly** - this is the absence of a major portion of the brain, skull and scalp that occurs during embryonic r. It is a cephalic disorder that results from a neural tube defect that occurs when the rostral (head) end of the neural tube fails to close, usually between the 23rd and 26th day of conception. With very few exceptions, infants with this disorder do not survive longer than a few hours or possibly days after birth.

**Spina bifida** - this is a developmental congenital disorder caused by the incomplete closing of the embryonic neural tube. Some vertebrae overlying the spinal cord are not fully formed and remain unfused and open. If the opening is large enough, this allows a portion of the spinal cord to protrude through the opening in the bones. There may or may not be a fluid – filled sac surrounding the spinal cord. Spina bifida malformations fall into three categories: spina bifida occulta, spina bifida cystic with meningocele, and spina bifida cystic with myelomeningocele. The most common location of the malformations is the lumbar and sacral areas. Spina bifida can be surgically closed after birth, but this does not restore normal function to the affected part of the spinal cord.

### **Self – Assessment Exercises**

1. describe the transformation of the neural tube into the different parts of the definitive brain.
2. differentiate between the events that lead to the formation of the brain and the spinal cord.
3. discuss the cellular formation, differentiation and migration, and the role of such processes in the formation of the brain and spinal cord.

## **4.0 CONCLUSION**

The CNS is an ectodermal derivative that begins to differentiate in the 3rd intrauterine week in humans.

## **5.0 SUMMARY**

- The first indication of the nervous system is within the neural plate, a thickened area of the ectoderm that forms after the ovum has been fertilised in the third week of gestation.

- The neural plate thickens rostral to the primitive node and midline depression in the neural plate forms the neural groove. Edges of the neural groove rise on both sides of the midline, fusing to convert the groove to a tube. The neural tube is the beginning of the brain and spinal cord. As the neural tube separates from the surface ectoderm cells, the neural folds form the neural crest. Ganglia of the spine, cranial and autonomic nervous system develop from the neural crest.
- Anomalies of the closure of the neural tube results in several clinical conditions such as anencephaly and spinal bifida.
- The 4th week witnesses the differentiation of the cranial part of the neural tube into the 3 brain vesicles which leads to the formation of the prosencephalon, mesencephalon and rhombencephalon cranio-caudally. Same mechanism results in the formation of 2 flexures, cervical and cephalic flexures. Cephalic flexure opens to the ventral surface while the cervical opens to the dorsal surface.
- By the 5th week of development, the Prosencephalon is divided into the Telencephalon and Diencephalon by differential growth rate. The Rhombencephalon also divides into the cranial Metencephalon and caudal Myelencephalon roughly by the cephalic (Pontine) flexure.
- The neuroblast of the cerebral cortex proliferates rapidly around the ventricle, forming neurons and supporting (glia) cells. The glial cells differentiate into the oligodendrocyte and astrocyte.

## **6.0 TUTOR MARK ASSIGNMENTS**

1. What is the neural plate?
2. What are the differences between the right and left hemispheres of the brain?
3. What are the primitive general functional areas of the brain?
4. When do the fontanelles of the skull close?

## UNIT 2 THE SPINAL CORD

### CONTENTS

- 1.0 Introduction
- 2.0 Objectives
- 3.0 Main Content
  - 3.1 General structure of the spinal cord
  - 3.2 Meninges of the spinal cord
  - 3.3 Internal structure of the spinal cord
  - 3.4 Clinical correlate
- 4.0 Conclusion
- 5.0 Summary
- 6.0 Tutor Marked Assignments
- 7.0 References and other resources

### 1.0 INTRODUCTION

The **spinal cord** is extremely important to the overall function of the nervous system. It is the major communication link between the brain and the PNS (spinal nerves) inferior to the head. The spinal cord participates in the integration of incoming information and produces responses through reflex mechanisms.

### 2.0 OBJECTIVES

At the end of this unit, you will be able to:

- discuss the parts of the spinal cord
- describe the three meningeal layers surrounding the spinal cord and brain
- describe the spinal cord in cross section and the origin of spinal nerves
- describe the blood supply of the spinal cord

### 3.0 MAIN CONTENT

#### 3.1 General structure of the spinal cord

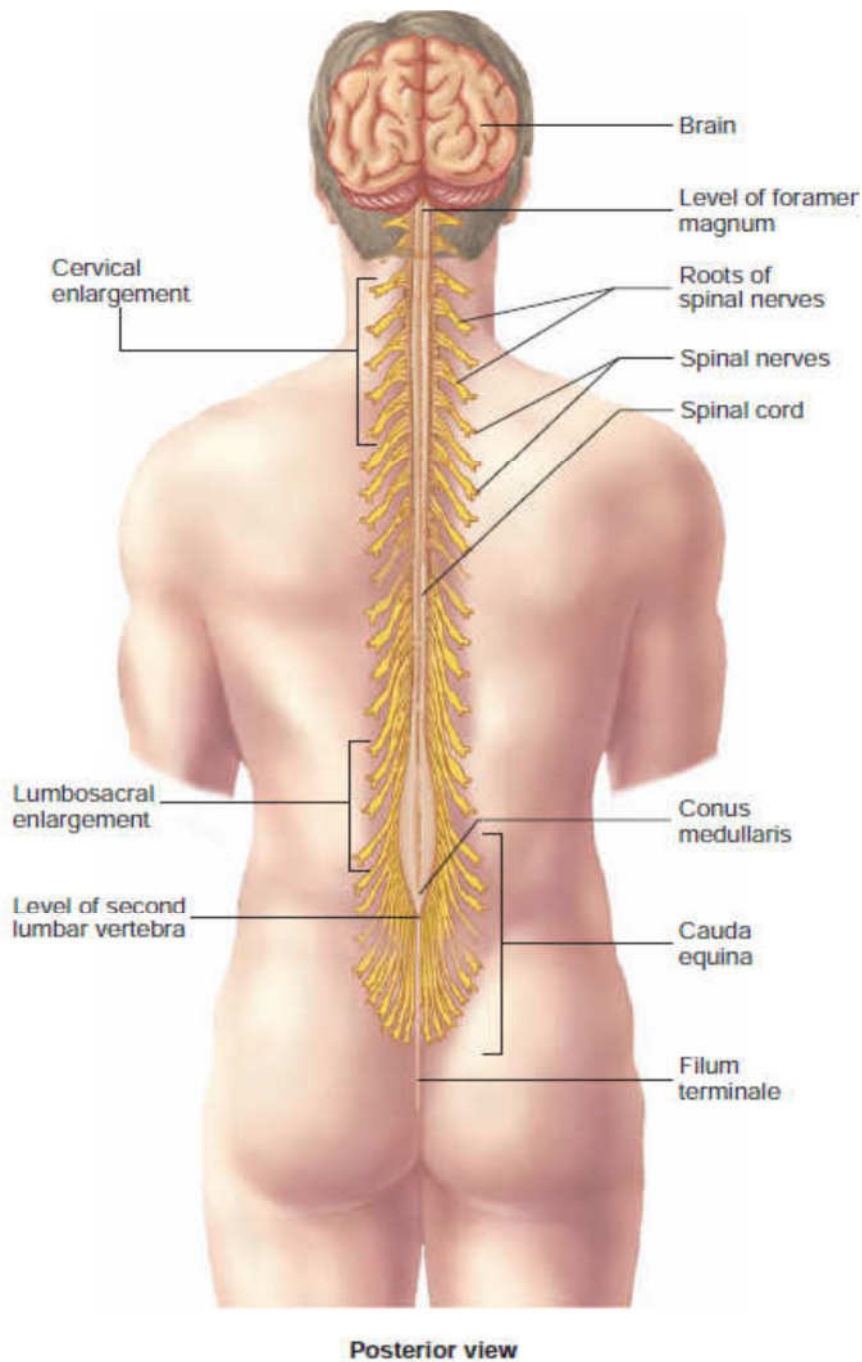
The spinal cord connects to the brain at the level of the foramen magnum and extends inferiorly in the vertebral canal to level L1–L2 of the vertebral column. It is considerably shorter than the vertebral column because it does not grow as rapidly as the vertebral column during development. The spinal cord gives rise to 31 pairs of spinal nerves,

which exit the vertebral column through intervertebral and sacral foramina.

Develops from the caudal portion of the neural tube, it is a region of less differentiation. It consists of 31 segments conferred by the emergence of the spinal nerves; cervical -8, thoracic- 12, lumbar-5, sacral-5, coccygeal- 1. Measuring about 42-45cm in adult.

The spinal cord is not uniform in diameter throughout its length. The **cervical enlargement** in the inferior cervical region is where spinal nerves supplying the upper limbs originate. The **lumbosacral enlargement** in the inferior thoracic, lumbar, and superior sacral regions is the site where spinal nerves supplying the lower limbs originate.

Immediately inferior to the lumbosacral enlargement, the spinal cord tapers to form a conelike region called the **conus medullaris**. Nerves arising from the inferior lumbosacral enlargement and the conus medullaris extend inferiorly through the vertebral canal before exiting the vertebral column. The numerous roots (origins) of these nerves resemble the hairs in a horse's tail and are therefore called the **cauda equine**



*The spinal cord and segments*

### **3.2 Meninges of the spinal cord**

The spinal cord is a long cylindrical structure with flattened anteroposterior surfaces. The spinal cord and brain are surrounded by connective tissue membranes called **meninges**. The most superficial and thickest membrane is the **dura mater**. The dura mater forms a sac, often called the **thecal sac**, which surrounds the spinal cord. The thecal sac attaches to the rim of the foramen magnum and ends at the level of the second sacral vertebra. The spinal dura mater is continuous with the dura mater surrounding the brain and the connective tissue surrounding

the spinal nerves. The dura mater around the spinal cord is separated from the periosteum of the vertebral canal by the **epidural space**, which contains spinal nerves.

### 3.3 Internal structure of the spinal cord

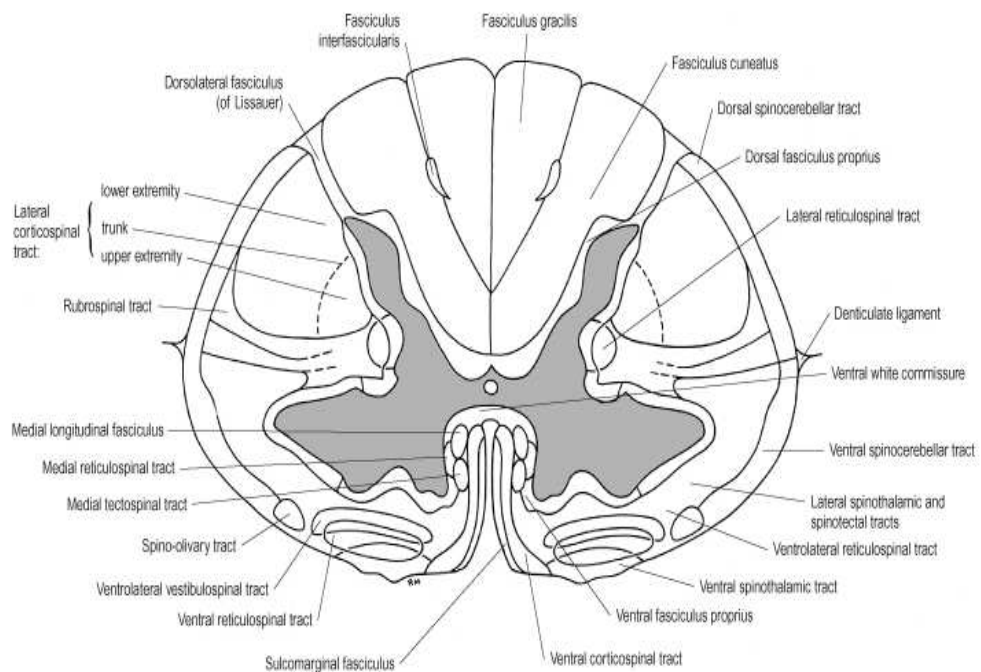
The internal structure of the spinal cord consists of the white and gray matter.

White matter is a collection of myelinated fibres, while cellular aggregates are in the gray matter.

H-shaped gray matter located within the cylindrical white matter, bridge of the h incorporating the central canal. Dorsal limbs of the h form the posterior horn which extends close to surface.

The anterior horns are farther away from the surface. The medial anterior horn cell innervate trunk muscles, lateral part supplies the limbs. Ventral part of lateral horn supplies the proximal muscles while dorsal part supplies distal muscles of limbs. The white matter is bounded by the limbs of the H-shaped gray matter are grouped as the anterior, posterior and lateral white column.

A narrow white commissure separates the anterior median fissure from the grey commissure.



## Spinal segments

Segmental differences exist with respect to the size of the grey horn and the white column.

**Cervical segment;** large oval shaped structure, relatively larger white matter. Posterior horn is smaller than the anterior. Posterior intermediate septum divides the posterior column into graciles and cuneatus. The posterior horn is enlarged from the C5 level downwards. Reticular process is at the base of the posterior horn.

**Thoracic segments;** the gray matter is relatively smaller than the white matter. Gracilis and cuneatus extend as far as mid thoracic segments, while gracilis continues caudally. T1 is more of a cervical in outline and gray and white matter proportion. Lateral horn at the base of the anterior horn, give rise to the preganglionic sympathetic efferent. Dorsal nucleus of Clarke located on the medial side of the base of the posterior horn, most obvious in T10-T12.

**Lumbar segment;** almost circular in transverse section. White matter proportionally less than gray matter. Gracilis has thinned out. Blunt lateral process on the lateral side of the base of stout anterior horn. Dorsal nucleus of Clarke in L1-L2.

**Sacral segment;** small cylindrical structure. Gray matter relatively more than the white matter.

Thickened gray commissure, posterior and anterior horn. Small lateral horn for the preganglionic parasympathetic cells.

## 3.4 Clinical correlates

### Introduction of Needles into the Subarachnoid Space

Several clinical procedures involve the insertion of a needle into the subarachnoid space inferior to the level of the second lumbar vertebra. The needle is introduced into either the L3/L4 or the L4/L5 intervertebral space. The needle does not contact the spinal cord because the spinal cord extends only approximately to the second lumbar vertebra of the vertebral column. The needle enters the subarachnoidspace, which extends to level S2 of the vertebral column. The needle does not damage the nerve roots of the cauda equine located in the subarachnoid space because the needle quite easily pushes them aside. In **spinal anesthesia**, or spinal block, drugs that block action



potential transmission are introduced into the subarachnoid space to prevent pain sensations in the lower half of the body.

A **spinal tap** is the removal of CSF from the subarachnoid space. A spinal tap may be performed to examine the CSF for infectious agents (meningitis), for the presence of blood (hemorrhage), or for the measurement of CSF pressure. A radiopaque substance may also be injected into this area, and a **myelogram** (radiograph of the spinal cord) may be taken to visualize spinal cord defects or damage.

Damage to the spinal cord can disrupt ascending tracts from the spinal cord to the brain, resulting in the loss of sensation, and/or descending tracts from the brain to motor neurons in the spinal cord, resulting in the loss of motor functions. Automobile and motorcycle accidents are leading causes, followed by gunshot wounds, falls, and swimming accidents. Spinal cord injury is classified according to the vertebral level at which the injury occurred, whether the entire cord is damaged at that level or only a portion of the cord, and the mechanism of injury. Most spinal cord injuries occur in the cervical region or at the thoracolumbar junction and are incomplete.

### **Self – Assessment Exercise**

- discuss the parts of the spinal cord
- describe the three meningeal layers surrounding the spinal cord and brain
- describe the spinal cord in cross section and the origin of spinal nerves
- describe the blood supply of the spinal cord

## **4.0 CONCLUSION**

The spinal cord connects to the brain at the level of the foramen magnum and extends inferiorly in the vertebral canal to level L1–L2 of the vertebral column. It is considerably shorter than the vertebral column because it does not grow as rapidly as the vertebral column during development.

## **5.0 SUMMARY**

- The spinal cord gives rise to 31 pairs of spinal nerves. The spinal cord has cervical and lumbosacral enlargements from which spinal nerves of the limbs originate.
- The spinal cord is shorter than the vertebral column. Nerves from the end of the spinal cord form the cauda equina.

- Three meningeal layers surround the spinal cord. From superficial to deep they are the dura mater, arachnoid mater, and pia mater.
- The epidural space is between the periosteum of the vertebral canal and the dura mater, the subdural space is between the dura mater and the arachnoid mater, and the subarachnoid space is between the arachnoid mater and the pia mater.
- Gray matter is divided into horns. The dorsal horns contain sensory axons that synapse with interneurons. The ventral horns contain the neuron cell bodies of somatic motor neurons, and the lateral horns contain the neuron cell bodies of autonomic motor neurons.
- The dorsal root contains sensory axons, the ventral root has motor axons, and spinal nerves have sensory and motor axons.

## 6.0 TUTOR MARKED ASSIGNMENTS

- I. In the anatomy museum, identify the major features on the models and slide of a cross – section of the spinal cord; also note the three layers of the meninges on the cross- section models.
  1. The spinal cord extends from the
    - a. medulla oblongata to the coccyx.
    - b. level of the third cervical vertebra to the coccyx.
    - c. level of the axis to the lowest lumbar vertebra.
    - d. level of the foramen magnum to level L1–L2 of the vertebral column.
    - e. axis to the sacral hiatus.
  2. Axons of sensory neurons synapse with the cell bodies of interneurons in the of spinal cord gray matter.
    - a. anterior horn
    - b. lateral horn
    - c. posterior horn
    - d. gray commissure
    - e. lateral funiculi
  3. Cell bodies for spinal sensory neurons are located in the
    - a. anterior horn of spinal cord gray matter.
    - b. lateral horn of spinal cord gray matter.
    - c. posterior horn of spinal cord gray matter.
    - d. dorsal root ganglia.
    - e. posterior columns.

4. Contrast the epidural and the subarachnoid spaces.
5. Describe the appearance of the spinal cord in cross section.
6. Discuss the anatomy of the terminal portion of the spinal cord.

## **7.0 REFERENCES AND OTHER RESOURCES**

Hutchinson, M., Mallat, J., Marieb, E.N., Wilhelm P.B. (2007). A Brief Atlas of the Human Body. Sna Franciscio: Pearson Education Inc.

Katherine M. A. Rogers and William N. Scott (2011) Nurses! Test Yourself in Anatomy and Physiology

Kathryn A. Booth, Terri. D. Wyman (2008) Anatomy, Physiology, and Pathophysiology for Allied Health

Keith L Moore, Persuade T.V.N (2018), The Developing Human Clinically Oriented Embryology 11th Edition Lippincott Williams & Wilkins

Kent M. Van De Graff, R.Ward Rhees, Sidney Palmer (2010) Schaum's Outline of human Anatomy and Physiology 3rd edition.

Philip Tate (2012) Seeley's Principles of Anatomy & Physiology 2nd ed.

Sadler T.W (2012), Langman's Medical Embryology 12th edition.

Seeley's Principles of Anatomy & Physiology, Second edition Published by McGraw-Hill, a business unit of The McGraw-Hill Companies, Inc., 1221 Avenue of the Americas, New York, NY 10020. Copyright c 2012- Chapter 17&18

## UNIT 3 BRAIN STEM

### CONTENTS

- 1.0 Introduction
- 2.0 Objectives
- 3.0 Main Content
  - 3.1 Cranial nerve nuclei
  - 3.2 Clinical correlates
- 4.0 Conclusion
- 5.0 Summary
- 6.0 Tutor Marked Assignments
- 7.0 References and other resources

### 1.0 INTRODUCTION

The Brain Stem is a structural connection between the diencephalon and the spinal cord. The **brainstem** consists of the medulla oblongata, pons, and midbrain. It connects the spinal cord and cerebellum to the remainder of the brain, and 10 of the 12 pairs of cranial nerves arise from it. In general, the posterior part of the brainstem contains ascending tracts from the spinal cord, cerebellum, and cranial nerves, whereas the anterior part of the brainstem contains descending tracts involved with motor control. The brainstem contains several nuclei involved in vital body functions, such as the control of heart rate, blood pressure, and breathing.

The caudal portion of the brain stem transit into the spinal cord at the level of the foramen magnum. It contains ascending and descending fibers interspersed with cellular aggregate known as the nuclei. The corticospinal (motor), posterior column (fine touch, vibration sense and proprioception) and spinothalamic (crude touch, temperature and pain).

### 2.0 OBJECTIVES

At the end of this unit, you will be able to:

- to describe the anatomy of the different parts of the brain stem.
- to identify the characteristic features of the midbrain, pons and medulla oblongata.

### 3.0 MAIN CONTENT

#### 3.1 Cranial nerve nuclei

The cranial nerve nuclei 3-12 are located in the brain stem in addition to other anatomically distinct nuclei.

The midbrain contains CN 3, 4

The Pons contains CN 5, 6, 7

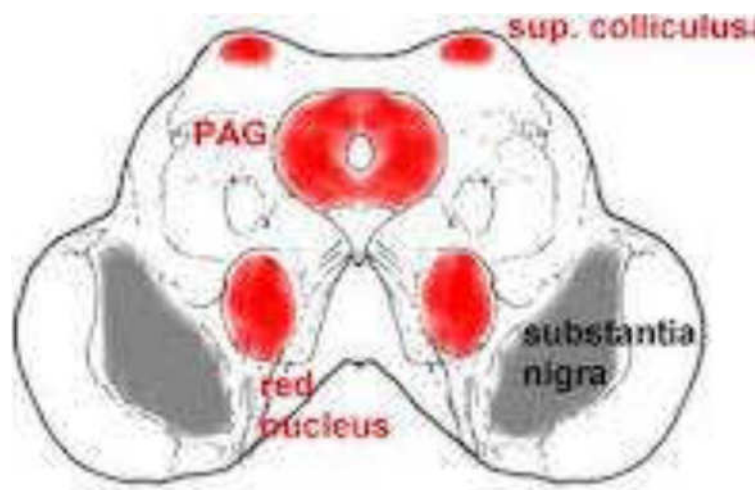
The Medulla contains CN 9, 10, 11, 12

The CN 8 is located in the pontomedullary junction. Diffuse cellular arrangements are also located in the brain stem forming the Reticular system. The reticular formation is related to several vital centers. The sensory part of the CN 5 spans the whole of the brain stem as far as the upper spinal cord. All cranial nerves emerge from the ventral surface of the brain stem except the Trochlear.

### Mid-brain

It is the shortest part of the brainstem measuring about 2cm. Ventrally it is characterized by a V shaped crura that converge on the superior surface of the pons. Dorsally, the superior and inferior colliculi form 2 pairs of round elevation. The superior cerebellar peduncle connects the cerebellum to the dorsal surface of the midbrain caudal to the inferior colliculus.

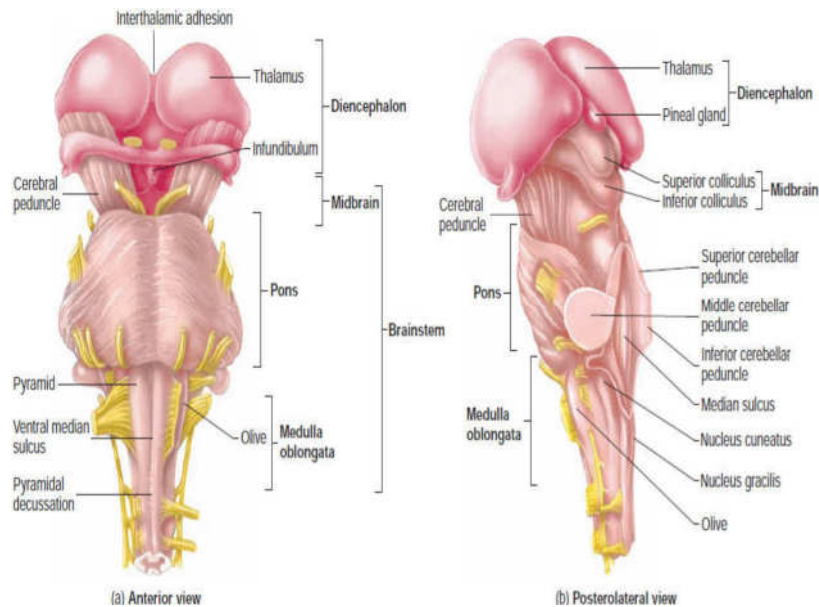
The medial geniculate body and lateral geniculate body are lateral to the superior colliculus, while the pineal gland and pulvinar are superiorly related.



- The CN 3 emerges from the ventral surface on the medial side of the cerebral peduncle, while the CN 4 courses ventrally from its point of emergence on the dorsal surface inferior to the inferior colliculus.

- The 2 CN run between the superior cerebellar and posterior cerebral arteries which provide blood supply for the midbrain.
- It is ventro-dorsally divisible into the base, tegmentum and tectum.
- Histologically the superior and inferior colliculi provide a logical reference point.
- Superior colliculus level; the oculomotor nucleus is close to midline with the Edinger-Westphal nucleus cranial to it. The red nucleus is lateral and ventral to CN 3, the axons of the CN pass through it. It receives input from the contralateral cerebellar hemisphere (dentate nucleus) via the superior cerebellar peduncle.
- Inferior colliculus level; the nucleus of CN 4 lie ventral to the aqueduct, its fibers run dorsally decussating dorsal to the aqueduct.
- The Substantia Nigra forms the boundary between the crus and the tegmentum. Its cells contain melatonin giving rise to nigrostriatal fibers.
- Fibers project to the other basal ganglia nuclei. Loss of dopamine producing cells explains Parkinsonism. Mesencephalic nucleus of CN 5 lies in the central gray matter, while spinal and medial lemnisci lie in the lateral region of tegmentum.
- The reticular formation is located between the medial lemniscus and the central gray matter.
- The crura contain corticospinal and corticonuclear fibers in the middle 2/3rd portion while frontopontine and temporopontine fibers occupy the medial and lateral 1/6th.
- The tectum is occupied by the superior and inferior colliculi with inputs from the retina and cochlea respectively.
- Efferent fibers travel in the tectospinal and tectobulbar tracts for general light and sound reflexes
- The pretectal nucleus is located at the junction between the midbrain and the diencephalon subserving the pupillary light reflexes.

### 3.3.4 Pons



#### The parts of the brainstem

The pons forms a bridge between the midbrain, medulla and the cerebellum. It contains the respiratory center. It's transversely running fibers coalesce to form the middle cerebellar peduncle. The motor and sensory part of the CN 5 emerges from its ventral surface just lateral to the midline.

A midline groove houses the basilar artery, while the superior cerebellar artery curves around its boundary with the midbrain. At the pontomedullary junction CN 6 emerges at the midline while CN 7 and 8 emerge more laterally. The cerebellum covers the dorsal surface of the pons with the pontine part of the 4th ventricle in between them. The central aqueduct opens directly into the 4th ventricle. The superior medullary velum (anchored on SCP) intervenes as the roof between the ventricle and the cerebellum. The upper part and lower part of the pons are distinguishable by the presence or absence of opened 4th ventricle. The ventral part of the pons has pontine nuclei with corticopontine fibers passing through them.

**Upper pons;** the motor nucleus of CN 5 is located on the lateral part of the floor of 4th ventricle, while the main sensory nucleus (touch) is lateral to it. The sensory nucleus is continuous with the mesencephalic nucleus (proprioception) in the midbrain.

**Lower pons;** the nucleus of CN 6 lie on the floor of the 4th ventricle near midline while that of CN 7 lies ventral and lateral to it. Fibers of

CN 7 course dorsal to the nucleus of CN 6 raising a facial colliculus on the floor of the 4th ventricle. The nucleus of CN 8 lie on the floor of the 4th ventricle lateral to the CN 7 extending to the medulla, the vestibular portion is more medial.

Vestibular part receives fibers from the internal acoustic meatus, while the cochlea part receives fibers from the spiral ganglia of cochlea. Both travel in the inferior cerebellar peduncle.

Blood supply is from the basilar artery superior cerebellar and anterior inferior cerebellar arteries.

### **Medulla oblongata**

This is the portion of the brain stem that connects the pons to the spinal cord. It is continuous with the spinal cord at the level of foramen magnum. Dorsally the upper part is covered by the cerebellum with the caudal part of the 4th ventricle intervening. This portion of the 4<sup>th</sup> ventricle is roofed by a layer of ependyma and pia matter.

The caudal part of the dorsal surface presents 2 elevations namely the gracile and cuneate tubercle secondary to underlying nuclei mediolaterally. Ventrally, the upper part is grooved in the midline, the pyramid and olive are elevations lateral to the midline. The pyramid is secondary to the corticospinal fibers while the olive is secondary to the inferior olivary nucleus. The most lateral elevation forms the lateral boundary, the inferior cerebellar peduncle.

The CN 6, 7 and 8 emerge from the pontomedullary junction mediolaterally. The CN 9, 10 and 11 emerge as rootlets lateral to olive and CN 12 between pyramid and olive. 3 levels of medulla are identifiable, the open part, the upper closed part and the lower closed part.

**Open part;** the floor of the 4th ventricle is the site of most cranial nerve nuclei. The hypoglossal nucleus is located adjacent to the midline beneath the hypoglossal trigone. The nucleus of the vagus is located lateral to the hypoglossal beneath the vagal trigone. It controls the cardiac and visceral muscle and glandular secretions. The nucleus of tractus solitarius lie lateral to that of vagal, its cranial part receives fibers from chorda tympani, glossopharyngeal and internal laryngeal branch of vagus.

The nucleus ambiguus lies lateral containing motor cell bodies for larynx, soft palate, pharynx and upper oesophagus skeletal muscles. The



inferior olivary nucleus is a crenated C-shaped strip of gray matter with its open end facing the opposite cerebellar peduncle.

**Upper closed part;** it shows the central decussation of the fibers that form the medial lemniscus (fibers of gracile and cuneate nuclei).

**Lower closed part;** it is characterized by the pyramidal decussation. Centre for the control of reflex activities such as coughing, swallowing and vomiting. Centers for the control of respiratory, cardiac and motor function are also located in the medulla.

Blood supply of the medulla: anterior spinal branch of vertebral artery (medial medullary syndrome).Posterior inferior cerebellar artery (lateral medullary syndrome).

### 3.2 Clinical correlates

**Parkinsonism:** this is a neurological syndrome characterized by tremor, hypokinesia, rigidity and postural instability. The neurodegenerative condition Parkinson's disease is the most common cause of Parkinsonism. The motor symptoms of this disease result from the death of dopamine – generating cells in the substantia nigra. Modern treatments are effective at managing the early motor symptoms of the disease, these include levodopa and dopamine agonists.

**Brainstem stroke syndromes:** there are a large number of well-defined brainstem stroke syndromes, most of which involve ischemia in the distribution of the basilar or vertebral arteries. Magnetic resonance imaging (MRI) is frequently needed to make a specific diagnosis.

### SELF – ASSESSMENT EXERCISE

- to describe the anatomy of the different parts of the brain stem.
- to identify the characteristic features of the midbrain, pons and medulla oblongata.

### 4.0 CONCLUSION

The Brain Stem is a structural connection between the diencephalon and the spinal cord. The brainstem consists of the medulla oblongata, pons, and midbrain

## 5.0 SUMMARY

- The midbrain is superior to the pons. The corpora quadrigemina consists of four colliculi. The two inferior colliculi are involved in hearing and the two superior colliculi in visual reflexes.
- The substantia nigra and red nucleus help regulate body movements. The cerebral peduncles are the major descending motor pathway
- The pons is superior to the medulla. Ascending and descending tracts pass through the pons. The pons connects the cerebrum and the cerebellum. Pontine nuclei regulate breathing, swallowing, balance, chewing, and salivation.
- The medulla oblongata is continuous with the spinal cord and contains ascending and descending tracts. Medullary nuclei regulate the heart, blood vessels, breathing, swallowing, vomiting, coughing, sneezing, hiccuping, balance, and coordination. The pyramids are tracts controlling voluntary muscle movement.

## 6.0 TUTOR MARKED ASSIGNMENT

1. Important centers for heart rate, blood pressure, breathing, swallowing, coughing, and vomiting are located in the
  - a. cerebrum.
  - b. medulla oblongata.
  - c. midbrain.
  - d. pons.
  - e. cerebellum.
2. In which of these parts of the brain does decussation of descending tracts involved in the conscious control of skeletal muscles occur?
  - a. cerebrum
  - b. diencephalon
  - c. midbrain
  - d. pons
  - e. medulla oblongata
3. Important respiratory centers are located in the
  - a. cerebrum.
  - b. cerebellum.
  - c. pons and medulla oblongata.
  - d. midbrain.

- e. limbic system
- 4. The cerebral peduncles are a major descending motor pathway found in the
  - a. cerebrum.
  - b. cerebellum.
  - c. pons.
  - d. midbrain.
  - e. medulla oblongata.
- 5. The superior colliculi are involved in, whereas the inferior colliculi are involved in
  - a. hearing, visual reflexes
  - b. visual reflexes, hearing
  - c. balance, motor pathways
  - d. motor pathways, balance
  - e. respiration, sleep

## 7.0 REFERENCES AND OTHER RESOURCES

- Hutchinson, M., Mallat, J., Marieb, E.N., Wilhelm P.B. (2007). A Brief Atlas of the Human Body. San Francisco: Pearson Education Inc.
- Katherine M. A. Rogers and William N. Scott (2011) Nurses! Test Yourself in Anatomy and Physiology
- Kathryn A. Booth, Terri. D. Wyman (2008) Anatomy, Physiology, and Pathophysiology for Allied Health
- Keith L Moore, Persuade T.V.N (2018), The Developing Human Clinically Oriented Embryology 11th Edition Lippincott Williams & Wilkins
- Kent M. Van De Graff, R.Ward Rhee, Sidney Palmer (2010) Schaum's Outline of human Anatomy and Physiology 3rd edition.
- Philip Tate (2012) Seeley's Principles of Anatomy & Physiology 2nd ed.
- Sadler T.W (2012), Langman's Medical Embryology 12th edition.
- Seeley's Principles of Anatomy & Physiology, Second edition Published by McGraw-Hill, a business unit of The McGraw-Hill Companies, Inc., 1221 Avenue of the Americas, New York, NY 10020. Copyright c 2012- Chapter 17&18

## **UNIT 4     DIENCEPHALON AND BASAL GANGLIA**

### **CONTENTS**

- 1.0 Introduction
- 2.0 objectives
- 3.0 Main Content
  - 3.1 Structure of the diencephalon
  - 3.2 Thalamus
  - 3.3 Basal ganglia
  - 3.4 Clinical correlates
- 4.0 Conclusion
- 5.0 Summary
- 6.0 Tutor Marked Assignments
- 7.0 References and other resources

### **1.0 INTRODUCTION**

The forebrain consists largely of white matter with buried grey matter aggregates.

Largest grey matter aggregate is the thalamus. Other grey matter aggregate lies lateral to the thalamus known as the basal ganglia/nuclei. The unexpanded portion of the forebrain that is in the midline is known as the diencephalon. The grey matter aggregates are lateral relations of the diencephalon, the thalamus more medial than the basal ganglia.

### **2.0 OBJECTIVES**

At the end of this unit, you will be able to:

- describe the diencephalon and basal ganglia
- discuss the anatomy of the thalamus and its surrounding structures
- discuss the anatomical basis of Parkinson's disease.

### **3.1 Structure of the diencephalon**

The 3rd ventricle is the cavity of the diencephalon. It is a slit-like space which lies in the sagittal plane roofed by the fornix and the corpus callosum. The lateral wall of the 3rd ventricle is largely formed by the thalamus. The thalamus is separated from the hypothalamus on the lateral wall of the 3rd ventricle by the hypothalamic sulcus. The sulcus runs from the interventricular foramen towards the aqueduct of the midbrain. The lower part of the lateral wall and the floor of the 3<sup>rd</sup> ventricle is formed by the hypothalamus. The optic chiasma forms the

anterior end of the floor of the 3rd ventricle. The infundibulum is just behind the optic chiasma and projects downward forming the pituitary stalk. The pituitary stalk provides a path of communication between the hypothalamus and the posterior lobe of pituitary gland. Other features on the external surface of the floor are mammillary bodies and posterior perforated substance.

The median eminence is the portion of the floor just behind the infundibulum. It contains cells that control the anterior pituitary gland. The anterior wall of the 3rd ventricle is the lamina terminalis extending from the anterior commissure to the optic chiasma. The body of the fornix separates the anterior commissure from the interventricular foramen. Between the rostrum, genu and body of the corpus callosum and the body of the fornix is a 2 ply thin partition known as the septum pellucidum. The roof is formed by pia matter which covers the superior surface of the thalamus. The roof is invaginated by the pair of choroid plexus.

The posterior wall tapers towards the midbrain. The pineal gland projects posteriorly from the posterior wall, above the superior colliculus. This small conical body secretes melatonin, its stalk is attached to the posterior commissure. Calcification of the pineal gland is common after 40 years and is thus useful for radiologist as an indicator of brain symmetry.

### **3.2 Thalamus**

It is the largest of the cellular aggregate of the forebrain. It forms the lateral wall of the diencephalon. The medial surfaces of the thalamus lie parallel to each other slightly bulging into the 3rd ventricle. An interthalamic adhesion joins the 2 thalami in about 60-80% of cases, there is however no exchange of substance via this connection. The pulvinar is the posterior end of the medial surface of the thalamus. The opening of the interventricular foramen forms the anterior limit of the thalamus, while the posterior commissure is the posterior limit. It extends from the 3rd ventricle to the medial side of the posterior limb of the internal capsule.

The superior surface of the thalamus tapers anteriorly from the pulvinar to the small anterior pole. The pia matter covering of the superior surface extends to the pulvinar as far backward as the pineal gland. The lateral edge of the superior surface is covered by ependyma and forms part of the floor of the lateral ventricle. The substance of the thalamus is divided into lateral, medial and anterior portions by the sheet of white matter known as the internal medullary lamina.

The lateral surface is closely related to the internal capsule. Lateral boundary corresponds with the position of the stria terminalis and the terminal vein. The inferior surface is medially continuous with the hypothalamus separated by the hypothalamic sulcus.

The thalamic nuclei are grouped, following structural delineation by the internal medullary lamina and function.

**Anterior nuclei group;** the anterior end of the thalamus separated from the other part by the limbs of the internal medullary lamina. Connected to the mammillary body and projects to the cingulate gyrus.

**Medial nuclei group;** the gray substance medial to the internal medullary lamina, it projects to the frontal cortex.

**Lateral nuclei group;** mass of cells anterior to the pulvinar on the lateral side of the thalamus, project to different parts of the brain including motor cortex, postcentral gyrus and parietal lobe.

It receives fibres from the medial lemniscus, spinothalamic and trigeminal tracts.

**Posterior nuclei group;** this consists of the pulvinar and the medial and lateral geniculate bodies. The pulvinar is the large posterior nuclei that projects to the temporal and parietal lobes.

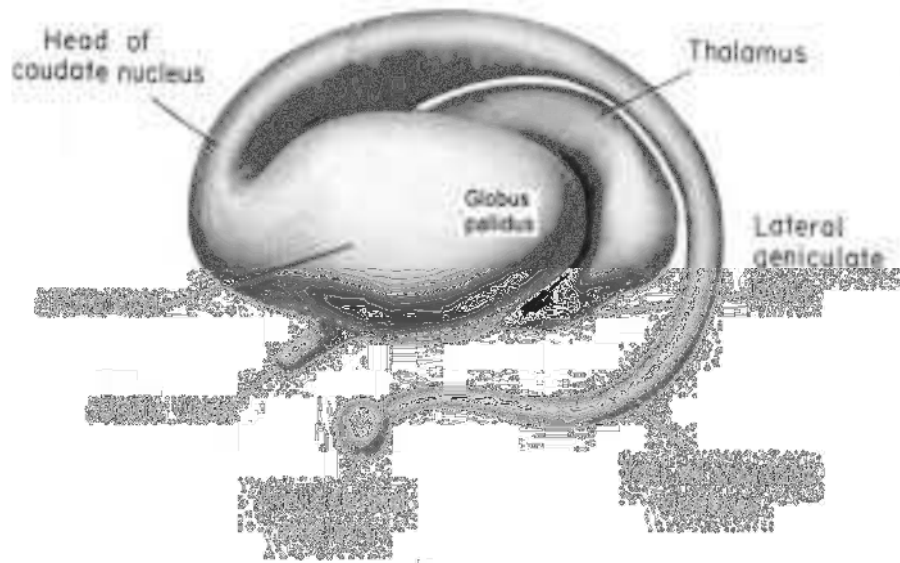
The medial geniculate body is ventral to the pulvinar and lateral to the midbrain, receives fibres from the lateral lemniscus and inferior colliculus, projects into the temporal lobe.

The lateral geniculate body is an oval elevation on the posterior end of the pulvinar, receives fibres from the optic tract and projects to the visual cortex.

### 3.3 Basal ganglia

This consist of the caudate nucleus, lentiform nucleus, amygdaloid body and claustrum. The lentiform nucleus consists of an outer putamen and an inner globus pallidus. The caudate and putamen form the striatum. It is the larger part of the basal ganglia and its afferent part.

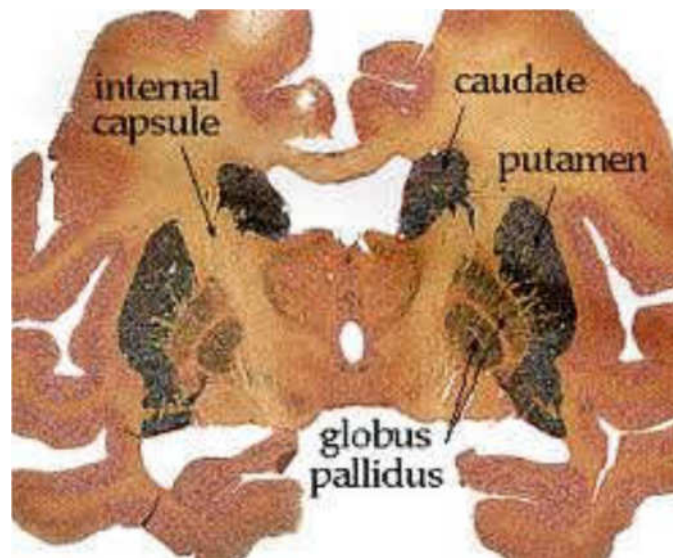
**Caudate nucleus:** It is a comma shaped structure with a demonstrable bulbous head, body and tail attached to the amygdaloid body.



### The basal ganglia

The convexity of the caudate nucleus projects into the ventricle. The internal capsule fibres run in the concavity of the nucleus. The lentiform nucleus; consist of the putamen and globus pallidus. It is biconvex in shape with the putamen lateral and smaller medial globus pallidus.

The caudate nucleus and the putamen are joined by many interconnecting fibre running through the anterior part of the internal capsule (corpus striatum).



**Amygdaloid body:** a group of grey matter at the tip of the tail of the caudate nucleus. It lies on the roof of the inferior horn of the lateral ventricle. It has numerous neurons that connect it to the frontal, temporal and olfactory lobes. Its efferent bundle (stria terminalis) runs parallel to the concavity of the caudate nucleus. The claustrum is a saucer shaped thin lamina of grey matter, lateral to the putamen.

## Functional anatomy

- The corpus striatum is the afferent centre of the basal ganglia receiving fibres from the cortex, thalamus and substantia nigra.
- The globus pallidus is the efferent pathway of the basal ganglia sending fibres to the thalamus, subthalamic nucleus, substantia nigra etc
- The basal ganglia offer supraspinal control over skeletal muscle movement, modulating the rate, range and coordination.
- Several neurotransmitter are involved in the different pathways such as the acetylcholine, dopamine, glutamate, serotonin etc
- Parkinsonism is the most common anomaly of the basal nuclei. It involves a decrease in dopamine in the nigrostriatal pathway following destruction of dopaminergic cells of the substantia nigra. Huntington's disease is as a result of destruction of the neurons in the striatum.

## 3.4 Clinical correlates

**Huntington's disease** - this is a neurodegenerative genetic disorder that affects muscle coordination and leads to cognitive decline and behavioural symptoms. The disease can affect both male and female and presents mostly in mid – adult life although physical symptoms can begin at any age. It is much more common in Western European people.

**Parkinsonism** - as discussed in the earlier unit.

### Self – Assessment Exercises

- describe the diencephalon and basal ganglia
- discuss the anatomy of the thalamus and its surrounding structures
- discuss the anatomical basis of Parkinson's disease

## 4.0 CONCLUSION

The basal ganglia are a group of structures found **deep within** the cerebral hemispheres. The structures generally included in the basal ganglia are the caudate, putamen, and globus pallidus in the cerebrum, the substantia nigra in the midbrain, and the subthalamic nucleus in the diencephalon



## 5.0 SUMMARY

- The diencephalon is located between the brainstem and the cerebrum. It consists of the thalamus, subthalamus, epithalamus, and hypothalamus.
- The thalamus consists of two lobes connected by the interthalamic adhesion. The thalamus functions as an integration center. All sensory input that reaches the cerebrum, except for the sense of smell, synapses in the thalamus. Pain is registered in the thalamus.
- The thalamus interacts with other parts of the brain to control motor activity. The thalamus is involved with emotions and pain perception. The subthalamus is inferior to the thalamus and is involved in motor function.
- The epithalamus is superior and posterior to the thalamus and contains the habenula, which influence emotions through the sense of smell. The pineal gland may play a role in the onset of puberty and the sleep–wake cycle.
- The hypothalamus is inferior to the thalamus. The hypothalamus is a major integrating center for the ANS, helping control heart rate, blood vessel diameter, urine release from the urinary bladder, and the movement of food through the digestive tract. The hypothalamus regulates body temperature, hunger, satiety, thirst, and swallowing and interacts with the reticular activating system.
- The hypothalamus is involved with sensations (sexual pleasure, good feelings, rage, and fear). The mammillary bodies are reflex centers for olfaction.

## 6.0 TUTOR MARKED ASSIGNMENTS

1. The major relay station for sensory input that projects to the cerebral cortex is the
  - a. hypothalamus.
  - b. thalamus.
  - c. pons.
  - d. cerebellum.
  - e. midbrain.
2. Which part of the brain is involved with olfactory reflexes and emotional responses to odours?
  - a. inferior colliculi
  - b. superior colliculi
  - c. mammillary bodies

- d. pineal gland
  - e. pituitary gland
3. Which of the following is a function of the hypothalamus?
- a. regulates autonomic nervous system functions
  - b. regulates the release of hormones from the posterior pituitary
  - c. regulates body temperature
  - d. regulates food intake (hunger) and water intake (thirst)
  - e. all of the above.

## 7.0 REFERENCES AND OTHER RESOURCES

Hutchinson, M., Mallat, J., Marieb, E.N., Wilhelm P.B. (2007). A Brief Atlas of the Human Body. Sna Francisco: Pearson Education Inc.

Katherine M. A. Rogers and William N. Scott (2011) Nurses! Test Yourself in Anatomy and Physiology

Kathryn A. Booth, Terri. D. Wyman (2008) Anatomy, Physiology, and Pathophysiology for Allied Health

Keith L Moore, Persuade T.V.N (2018), The Developing Human Clinically Oriented Embryology 11th Edition Lippincott Williams & Wilkins

Kent M. Van De Graff, R.Ward Rhees, Sidney Palmer (2010) Schaum's Outline of human Anatomy and Physiology 3rd edition.

Philip Tate (2012) Seeley's Principles of Anatomy & Physiology 2nd ed.

Sadler T.W (2012), Langman's Medical Embryology 12th edition.

Seeley's Principles of Anatomy & Physiology, Second edition Published by McGraw-Hill, a business unit of The McGraw-Hill Companies, Inc., 1221 Avenue of the Americas, New York, NY 10020. Copyright c 2012- Chapter 17&18

## UNIT 5 CEREBRAL HEMISPHERE

### CONTENTS

- 1.0 Introduction
- 2.0 Objectives
- 3.0 Main Content
  - 3.1 Superolateral surface
  - 3.2 Cortical area and structure
  - 3.3 Nails
  - 3.3 Clinical correlates
- 4.0 Conclusion
- 5.0 Summary
- 6.0 Tutor Marked Assignments
- 7.0 References and other resources

### 1.0 INTRODUCTION

The cerebrum is the part of the brain that most people think of when the term *brain* is mentioned. The cerebrum accounts for the largest portion of total brain weight, which is about 1200 g in females and 1400 g in males. Brain size is related to body size; larger brains are associated with larger bodies, not with greater intelligence.

The cerebrum is divided into left and right hemispheres by a longitudinal fissure. The most conspicuous features on the surface of each hemisphere are numerous folds called gyri, which greatly increase the surface area of the cortex. The grooves between the gyri are called sulci. The central sulcus, which extends across the lateral surface of the cerebrum from superior to inferior, is located about midway along the length of the brain. The general pattern of the gyri is similar in all normal human brains, but some variation exists between individuals and even between the two hemispheres of the same cerebrum.

Each cerebral hemisphere is divided into lobes, which are named for the skull bones overlying each one.

### 2.0 OBJECTIVES

At the end of this unit, you will be able to:

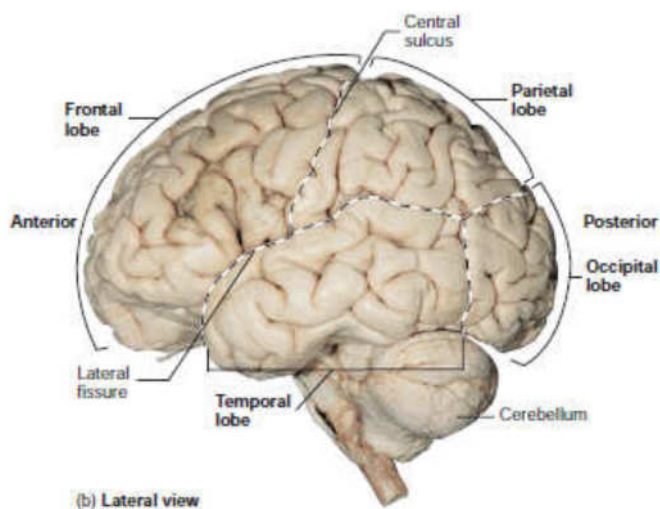
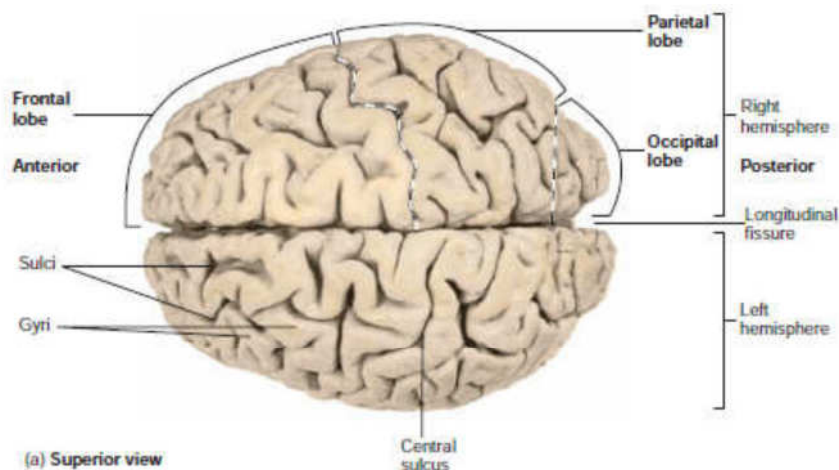
- Describe the different regions of the cerebral hemisphere.
- Identify the boundaries of the different regions of the cerebral hemisphere.

- Identify the different gyri and sulci as well as the functional areas of the cerebrum.

### 3.0 MAIN CONTENT

#### 3.1 Superolateral surface

Each lobe consists of gyri and sulci that have specific name. 3 main sulci delineate the boundary of the lobes, viz; central, lateral and parieto-occipital. Lateral sulcus (fissure of Sylvius) is the sulcus that separates the frontal from the temporal lobe. The anterior end of the sulcus penetrates (anterior and ascending rami) the inferior frontal gyrus dividing it into the Orbital, Triangularis and Operculum parts. Central sulcus; (fissure of Rolando) runs on the superolateral surface of the cerebrum just caudal to the antero-posterior midpoint. It runs downward and forward stopping short of the lateral sulcus. It separates the frontal from the parietal lobe. The precentral gyrus is just anterior to it, while the postcentral gyrus is just behind it.



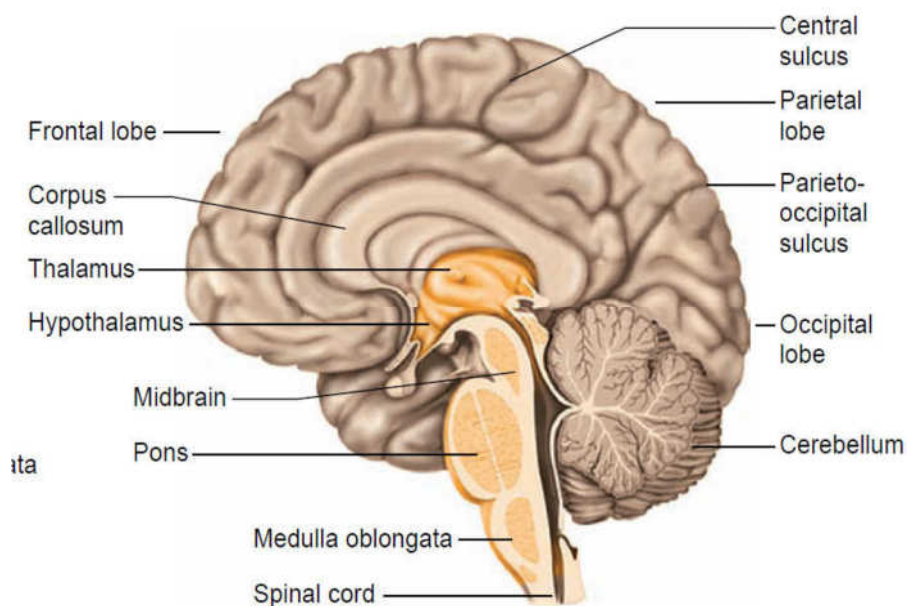
## Medial surface

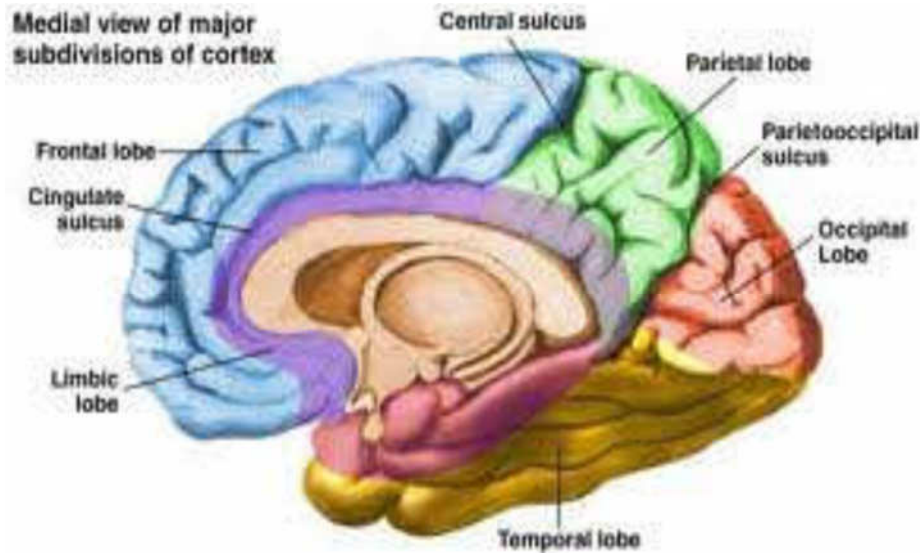
On the medial surface of the cerebral hemisphere, the corpus callosum stands out as a collection of white matter that connects the 2 hemisphere. The cingulate gyrus lies above the corpus callosum while the medial and superior frontal gyri lie above it separated by the cingulate sulcus.

The paracentral lobule caps the medial end of the central sulcus. The calcarine and parieto-occipital sulci form a Y shaped furrow lying on its side facing posteriorly. The precuneus gyrus lies above the upper arm and limb of the 'Y'. The cuneus gyrus lies in between the 2 arms of the 'Y' The lingual gyrus lies below the 'Y' at the inferio-medial border of the cerebrum. The inferior surface revealed the rectus gyrus, olfactory tract/bulb and orbital gyrus and sulcus from medial to lateral.

Parahippocampal gyrus lies medially on the inferior surface of temporal lobe terminate in the uncus

The brain stem is the other major structure on the inferior surface of an intact brain.





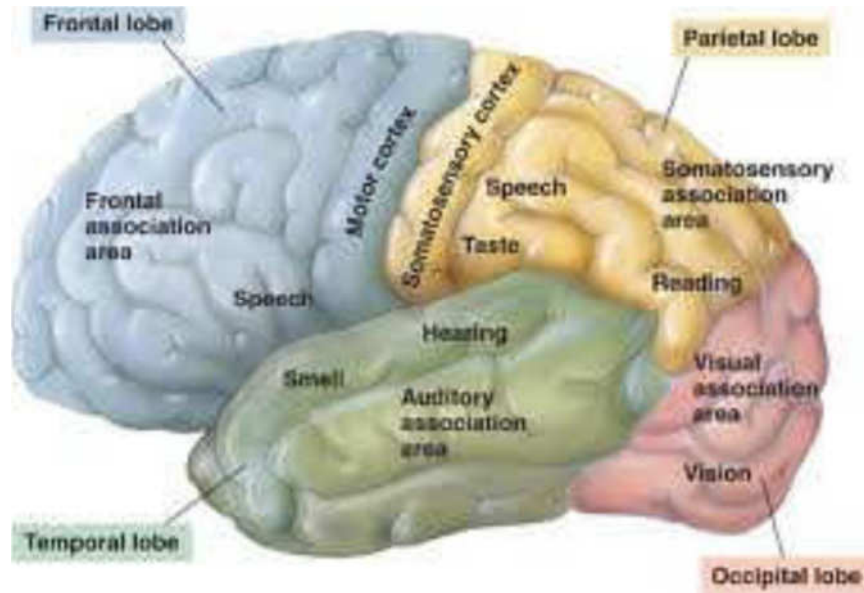
### 3.2 Cortical area and structure

The primary motor sensory area corresponds with the precentral gyrus and frontal lobe (Area 4 and 6). Afferent fibers exit via the corticonuclear and pyramidal bundles, modulated by the Thalamus and Cerebellum. The supplementary motor area corresponds with part of the medial surface of the frontal lobe (Area 6 and 8). The primary sensorimotor area corresponds with the postcentral gyrus and the adjoining medial surface of the parietal lobe (Area 3, 2 and 1). Subserve touch, kinaesthetic and vibration senses.

The inferior portion of postcentral gyrus corresponds with the supplementary sensory area (Area 40 and 43), subserve pain and temperature modalities. Anterior Motor speech area (Broca) corresponds to the inferior orbital gyrus of the dominant hemisphere and the pars triangularis (Area 44 and 45). Posterior speech area (Wernicke) is the posterior end of the superior and middle temporal gyri and the lower part of the parietal lobe.

Frontal eye field (Area 6, 8 and 9) is the centre of the middle frontal gyrus, it subserves the voluntary eye movement and accommodation functions.

Olfactory area corresponds with the Uncus and adjoining area. Visual area (Area 17) is the medial surface of occipital lobe, posterior lip of calcarine sulcus as far as the occipital pole. The striate cortex is the association visual area (Area 18 and 19). Auditory area (Area 41 and 42) is the floor of the lateral sulcus and the superior temporal gyrus, the surrounding Area 22 is the association area. Gustatory area is the inferior lip of the postcentral gyrus.



## CORTICAL STRUCTURE

The cerebral cortex consists of aggregates of cells in definite pattern. The assembly of cells is along morphological and functional lines. Over 90% of the cortex has a 6 layered arrangement.

- Layer I; plexiform or molecular layer, few cells mostly glia.
- Layer II; external granular layer, cells predominantly small granular type
- Layer III; external pyramidal, predominantly pyramidal cells.
- Layer IV; internal granular, consist of medium to large size granular cells.
- Layer V; internal pyramidal, pyramidal cells are medium to large size, giant pyramidal cells (Betz) characterise this layer
- Layer VI; multiform layer, different cell types are found in the layer. The ratio of granular to pyramidal cells in any layer is dependent on the modality it subserves

## Cerebral white matter

The white matter of the cerebrum is made up of fibres that can be grouped into 3 viz;

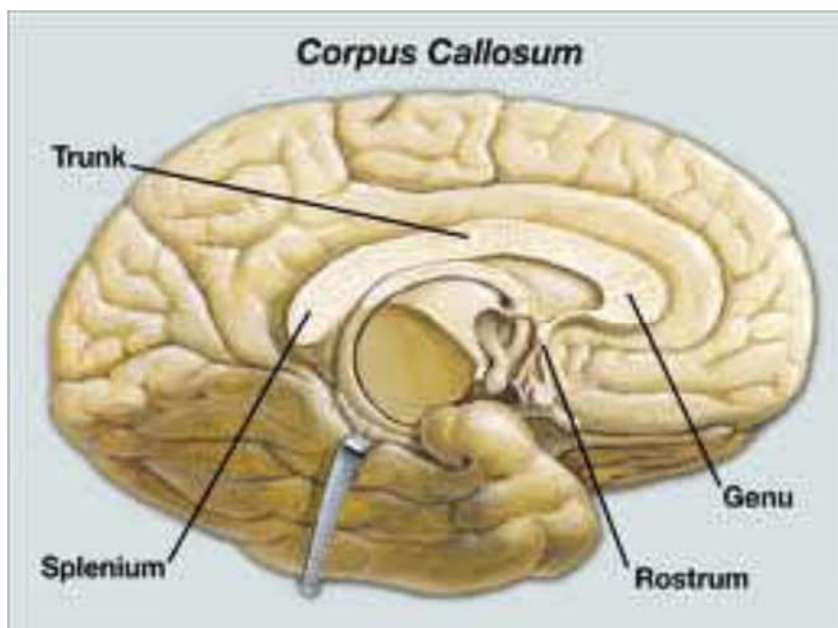
- **Commissural fibres**; these fibres connect the 2 cerebral hemispheres in a symmetrical fashion. They coalesce to form the corpus callosum, anterior and posterior commissures.
- **Association fibres**; they connect different parts of the same cerebral hemisphere.

- **Projection fibres;** they connect the grey matter of the cerebral hemisphere to subcortical nuclei in the brain stem, spinal cord etc.

### Commissural fibre

The corpus callosum is the most prominent commissural fibres collection.

It provides asymmetrical connection between the hemispheres. From its commencement at the anterior commissure it thickens posteriorly. It has 4 parts viz, Rostrum, Genu, Body, Splenium.



Forceps minor is formed by the laterally extending fibers of the genu, while that of the splenium form the Forceps major. Forceps minor connects the frontal cortex while Forceps major connects the occipital cortex. The laterally extending fibers of the remaining parts of the corpus callosum form a sheet of white matter that form the roof and lateral walls of the different parts of the lateral ventricles

### Projection fibres

The Internal capsule is the most prominent projection fibre. Consist of afferent fibres from thalamic nuclei and efferent fibres that travel through the cerebral peduncle of midbrain.

It is separated from the cavity of the lateral ventricle by the caudate nucleus. The globus pallidus of the lentiform nucleus indents its lateral edge conferring a lateral concavity on it. It has an anterior limb, a

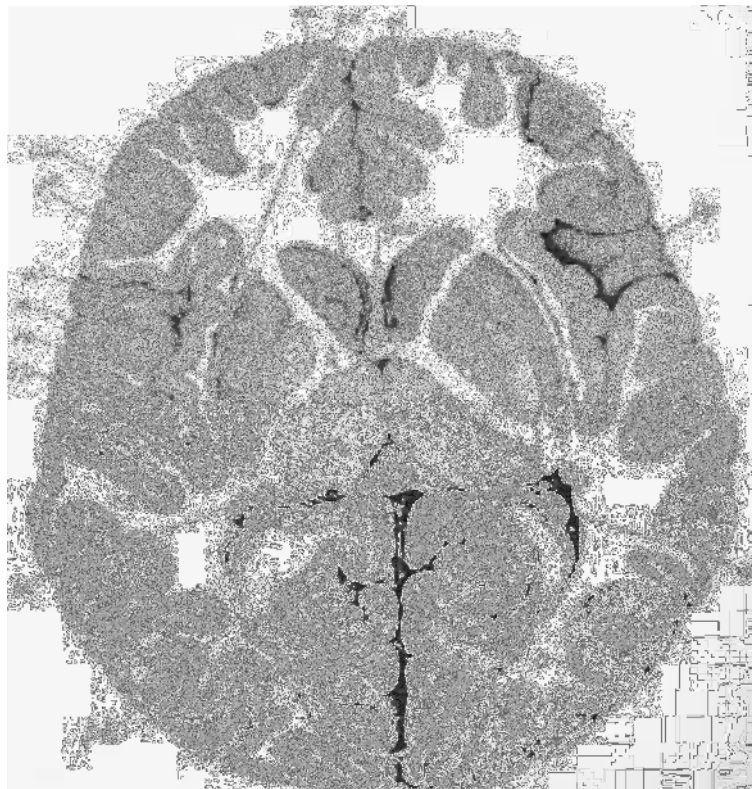

posterior limb connected by the genu. Retrolentiform and sublentiform parts are posteriorly located.

The Anterior Limb lies between the head of caudate (medially) and the lentiform (laterally) nuclei. Contain frontopontine fibres that travel from cell bodies in the frontal part of the cortex to the pontine nuclei on which they arborize. Passing through the thalamus they occupy the medial part of the base of the cerebral peduncle. Fibres from the frontal eye field to the oculomotor nucleus are suspected to pass through it. Genu is the bent portion of the internal capsule. Contain corticonuclear fibres from the cerebral cortex to the motor nuclei of cranial nerves in the brain stem.

Posterior limb is located between the Thalamus (medially) and the lentiform nucleus (laterally).

The anterior 2/3rd contains corticospinal fibers that travel from the cortical cell bodies to the anterior horn cells of the spinal cord. The fibers pass through the brainstem to the lower part of the medulla where most of them decussate to form the lateral corticospinal tract. Haemorrhage or thrombosis of the striate artery around the posterior fiber results in paralysis of the opposite skeletal muscles. Fibers of the Broca's speech are affected on the left side. Posterior 1/3rd of the posterior limb contain Thalamocortical fibers from thalamus to sensory cortex.



Retrolentiform part; located in the posterior end of lentiform nucleus, contains the corticopontine fibres which occupy the lateral part of the cerebral peduncle as well as optic radiations.

Sublentiform part is located below the posterior end of lentiform nucleus, contains auditory radiations from MGB to the auditory area of cortex.

### 3.3 Clinical correlates

- Head injuries are classified as open or closed. In an open injury the cranial cavity contents are exposed to the outside, whereas in a closed injury the cranial cavity remains intact. Closed injuries, which are more common than open injuries, involve the head striking a hard surface or an object striking the head. Such injuries may result in brain trauma.
- The most common type of traumatic brain injury (75%–90%) is a concussion, which is an immediate, but transient, impairment of neural function, such as a loss of consciousness or blurred vision. In some cases, postconcussion syndrome occurs a short time after the injury. The syndrome includes increased muscle tension or migraine headaches, reduced alcohol tolerance, difficulty in learning new things, reduction in creativity, changes in motivation, fatigue, and personality changes. The symptoms may be gone in a month or may persist for as long as a year.
- A hematoma is a localized mass of blood released from blood vessels but confined within an organ or a space. An accumulated mass of blood can apply pressure to the brain, causing damage to brain tissue. Blood is toxic to brain tissue. Hematomas of the brain are classified according to where the bleeding occurs. Epidural hematomas result from an accumulation of blood in the epidural space and occur in about 1%–2% of major head injuries. Subdural hematomas result from an accumulation of blood in the subdural space and occur in 10%–20% of major head injuries.

#### Self- Assessment Exercise

- Describe the different regions of the cerebral hemisphere.
- Identify the boundaries of the different regions of the cerebral hemisphere.
- Identify the different gyri and sulci as well as the functional areas of the cerebrum.

## 4.0 CONCLUSION

The cerebrum is divided into left and right hemispheres by a longitudinal fissure. The most conspicuous features on the surface of each hemisphere are numerous folds called gyri, which greatly increase the surface area of the cortex. The general pattern of the gyri is similar in all normal human brains, but some variation exists between individuals and even between the two hemispheres of the same cerebrum. Each cerebral hemisphere is divided into lobes, which are named for the skull bones overlying each one.

## 5.0 SUMMARY

- The cortex of the cerebrum is folded into ridges called gyri and grooves called sulci, or fissures. The longitudinal fissure divides the cerebrum into left and right hemispheres. Each hemisphere has five lobes.
- The frontal lobes are involved in voluntary motor function, motivation, aggression, the sense of smell, and mood. The parietal lobes contain the major sensory areas receiving sensory input, such as touch, pain, temperature, balance, and taste. The occipital lobes contain the visual centers. The temporal lobes evaluate smell and hearing input and are involved in memory, abstract thought, and judgment.
- Gray matter forms the cortex and nuclei of the cerebrum. White matter forms the cerebral medulla, which consists of three types of tracts (Association, Commissural and Projection fibers) connect cerebrum to other parts of the brain and the spinal cord.

## 6.0 TUTOR MARKED ASSIGNMENTS

1. Which of these cerebral lobes is important in voluntary motor function, motivation, aggression, sense of smell, and mood?
  - a. frontal
  - b. insula
  - c. occipital
  - d. parietal
  - e. temporal
2. Fibers that connect areas of the cerebral cortex within the same hemisphere are:
  - a. projection fibers.
  - b. commissural fibers.
  - c. association fibers.
  - d. all of the above.

3. The basal nuclei are located in the
  - a. inferior cerebrum.
  - b. diencephalon.
  - c. midbrain.
  - d. all of the above.
4. Describe the two layers of the cerebrum. Why is the outer layer convoluted?
5. Distinguish between a sulcus and a fissure.

## 7.0 REFERENCES AND OTHER RESOURCES

Hutchinson, M., Mallat, J., Marieb, E.N., Wilhelm P.B. (2007). A Brief Atlas of the Human Body. Sna Franscisco: Pearson Education Inc.

Katherine M. A. Rogers and William N. Scott (2011) Nurses! Test Yourself in Anatomy and Physiology

Kathryn A. Booth, Terri. D. Wyman (2008) Anatomy, Physiology, and Pathophysiology for Allied Health

Keith L Moore, Persuade T.V.N (2018), The Developing Human Clinically Oriented Embryology 11th Edition Lippincott Williams & Wilkins

Kent M. Van De Graff, R.Ward Rhees, Sidney Palmer (2010) Schaum's Outline of human Anatomy and Physiology 3rd edition.

Philip Tate (2012) Seeley's Principles of Anatomy & Physiology 2nd ed.

Sadler T.W (2012), Langman's Medical Embryology 12th edition.

Seeley's Principles of Anatomy & Physiology, Second edition Published by McGraw-Hill, a business unit of The McGraw-Hill Companies, Inc., 1221 Avenue of the Americas, New York, NY 10020. Copyright c 2012- Chapter 17&18

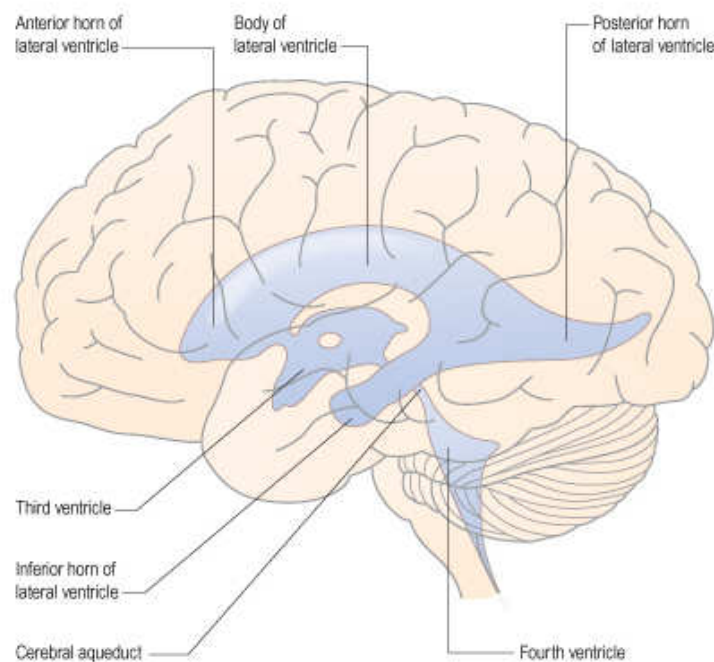
## UNIT 6 THE VENTRICLES AND CEREBROSPINAL FLUID

### CONTENTS

- 1.0 Introduction
- 2.0 Objective
- 3.0 Main Content
  - 3.1 Lateral ventricle
  - 3.2 Cerebrospinal fluid (CSF)
  - 3.3 Clinical correlates
- 4.0 Conclusion
- 5.0 Summary
- 6.0 Tutor Marked Assignments
- 7.0 References and other resources

### 1.0 INTRODUCTION

The ventricles are cavities within the brain for the production and drainage of Cerebrospinal fluid (CSF). It consists of the lateral ventricles, the 3rd ventricle and the 4th ventricle. The ventricular system of the brain is continuous with the central canal of the spinal cord. The ventricles contain CSF that cushions the brain and spinal cord within its bony container as well as provide nourishment. They are modified derivative of the neural canal.



## 2.0 OBJECTIVES

At the end of this unit, you will be able to:

- Differentiate the parts of the ventricular system and relate them to the different regions of the brain.
- Describe the walls of the different parts of the ventricular system.
- Discuss the production and flow of the cerebrospinal fluid.

## 3.0 MAIN CONTENT

### 3.1 Lateral ventricle

It is a C-shaped continuous cavity within the cerebral hemisphere. It consists of the body, anterior, posterior and inferior horns. Its medial wall is marked by the slit like opening on the medial surface of the hemisphere. This marks the point of invagination of the pia matter and ependyma for the formation of the choroid plexus which produces the CSF.

The choroid plexus of the lateral ventricle is continuous with that of the 3<sup>rd</sup> ventricle. The lateral ventricle produces most of the CSF.

**Anterior Horn;** it is triangular in outline with the apex pointing laterally. The forceps minor forms the roof, while the floor is indented by the head of the caudate nucleus.

Laterally the roof and the floor converge while they are kept apart by the septum pellucidum on the medial side. The lateral ventricle communicates with the 3<sup>rd</sup> ventricle via the interventricular foramen of Monro located just behind the anterior column of fornix. It is also the point of continuation of the Choroid plexus of the body and 3<sup>rd</sup> ventricle.

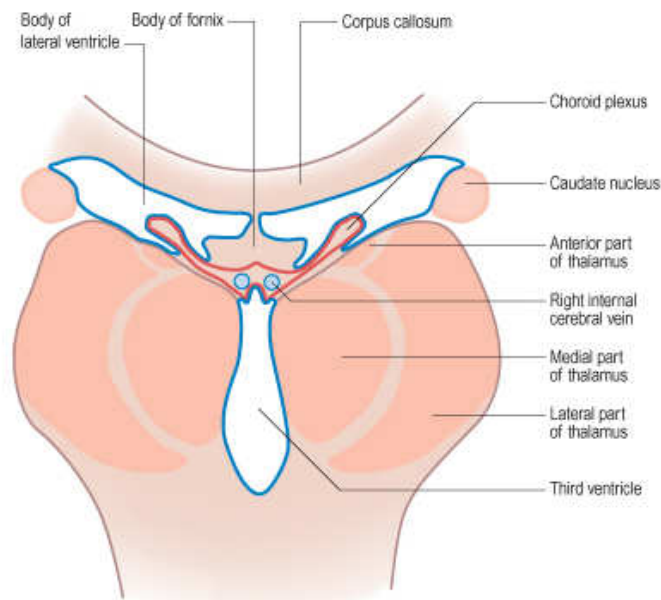
**Body;** the interventricular foramen of Monro is the boundary between the anterior horn and body. The Thalamus and the body of the caudate nucleus bulge into its floor. Thalamostriate vessels run between them. The roof is formed by the corpus callosum and the body of fornix.

Invagination of the choroid plexus is via the medial wall (septum pellucidum). Posterior Horn; the existence is variable. The collateral eminence bulges on its floor. 2 bulges are on the medial wall, upper bulb of posterior horn and lower calcar avis. The 2 can obliterate the horn. The tapetum forms the roof and lateral wall. The optic radiation is related to the lateral wall.

**Inferior Horn;** it is the largest part of the ventricles. The Hippocampus (medial) and the collateral eminence (lateral) form the floor of the horn. The tail of the caudate nucleus forms the roof ending in a convexities formed by the amygdaloid body and pes hippocampi. Lateral wall formed by the tapetum.

### Third ventricle

It is a slit-like space beneath the fornix and corpus callosum. Bounded anteriorly by the anterior column of fornix and the interventricular foramen of Monro. The lateral wall is largely occupied by the thalamic bulge. The hypothalamic sulcus on the lateral wall connects the IVFM to the aqueduct of the midbrain.

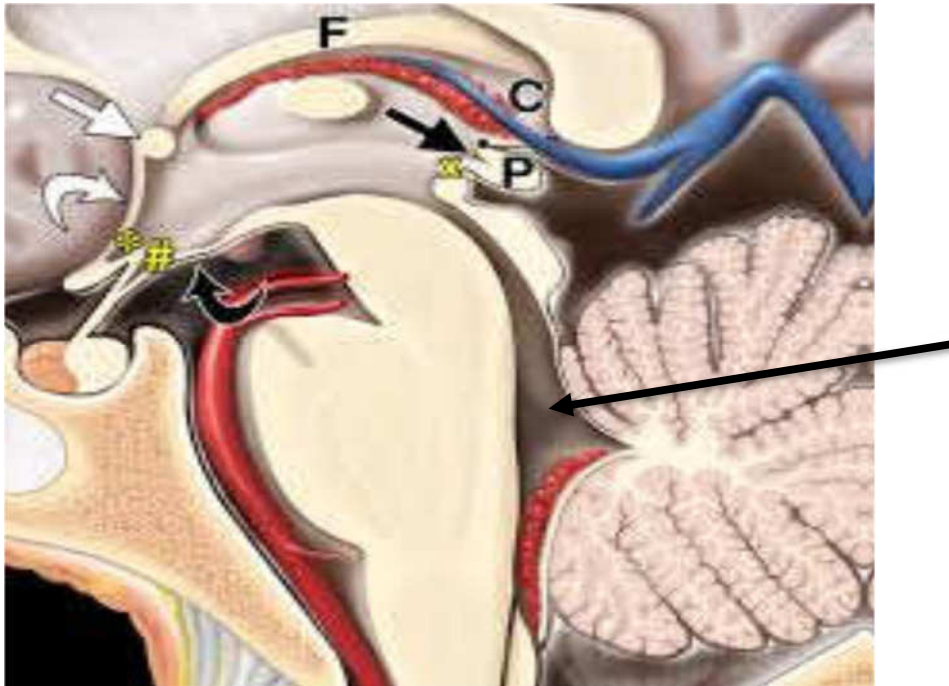


### Fourth ventricle

It communicates with the 3rd ventricle via the aqueduct of the midbrain. The pons and the upper medulla are ventral relations while the cerebellum is largely a supero-dorsal relation. The floor is diamond shaped with a tent like roof. It is triangular in sagittal section. Caudally the lateral boundary of the floor is formed by the gracile and cuneate tubercles with the inferior cerebellar peduncle superimposed on them. The lateral boundary of the floor cranially is formed by the superior cerebellar peduncle.

A thin stretch of white matter (superior medullary velum) connects the 2 superior cerebellar peduncle forming the cranial part of the roof. The caudal part of the roof is formed by a combination of pia and ependyma.

The foramen of Magendie is a central opening of it. The cerebellomedullary cistern communicates via the foramen.



The narrow lateral recess has the foramen of Luschka that communicates with the pontine cistern. The T-shaped choroid plexus indents the cranial part of the roof. The floor (Rhomboid fossa) has a midline groove (median sulcus) which connects the aqueduct of Sylvius to the central canal of the spinal cord.

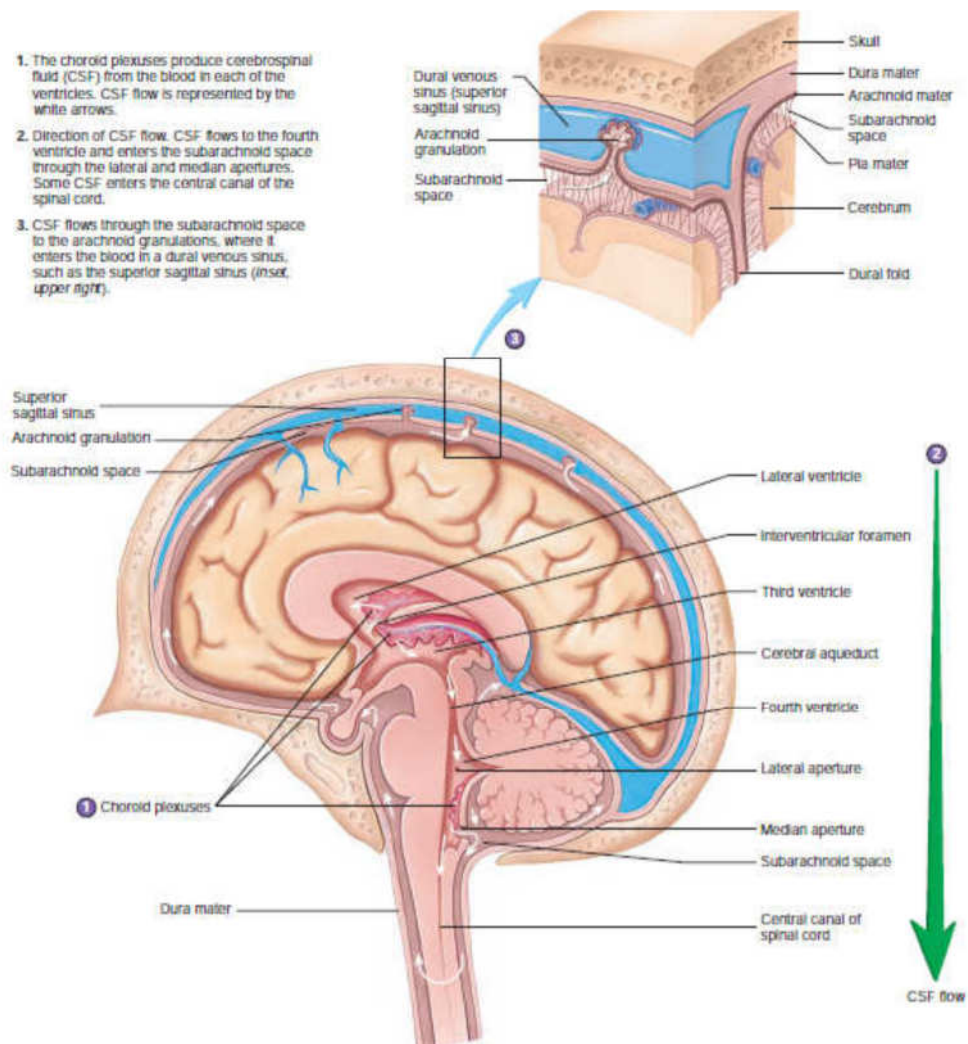
The cranial part of the floor is divided into the medial pontine part and lateral vestibular part. The pontine part of the floor has a bulge (facial colliculus) adjacent to the median sulcus. Laterally extending white matter (medullary striae) is found at the widest part of the floor. The vestibular area overlies the vestibular nuclei. The floor of the medullary part is divided into 2 by a faint groove that extends laterally from median sulcus towards the lateral recess. The medial small triangle (hypoglossal trigone) overlies the hypoglossal nucleus, while the lateral (vagal trigone) overlies the dorsal nucleus of vagus.

### 3.2 Cerebrospinal fluid (CSF)

It is produced by a modified ependymal cells and choroid plexus which is found in most part of the ventricular system. 70% of the CSF is produced from the ventricles while the remaining 30% is produced from brain capillaries. Total CSF volume is about 130ml, about 30ml is found in the ventricles while the subarachnoid space contains about 100ml. The body of the lateral ventricle and the 3rd ventricle are major site of production. The fluid drains through the IVFM to the 3rd ventricle,



through the Aqueduct of Sylvius to the 4th ventricle. It exits via the Foramina of Magendie and Luschka into the subarachnoid space or flow straight into the central canal of spinal cord. The fluid flows around the superior sagittal sinus and is reabsorbed via the arachnoid granulation into the venous system.



Flow of CSF

### 3.3 Clinical correlates

- I. **Lumbar puncture** is a sterile procedure done to withdraw C.S.F. from the spinal subarachnoid space and must be performed well clear of the termination of the cord. A line joining the iliac crests passes through the 4th lumbar vertebra and therefore the intervertebral spaces immediately above or below this landmark can be used with safety. The spine must be fully flexed (with the patient either on his side or seated) so that the vertebral interspinous spaces are opened to their maximum extent. The needle is passed inwards and somewhat cranially exactly in the midline and at right angles to the spine; the supraspinous and

interspinous ligaments are traversed and then the dura is penetrated, the latter with a distinct 'give'. Occasionally root pain is experienced if a root of the cauda equina is impinged upon, but usually these float clear of the needle. At spinal puncture C.S.F. can be obtained for examination; antibiotics, radio-opaque contrast medium or anaesthetics may be injected into the subarachnoid space, and the C.S.F. pressure can be estimated (normal, when lying on the side, 80–180mm C.S.F.).

## II. Hydrocephalus

CSF is produced at a rate of approximately 0.4 mL/min. If CSF returns to the blood at the same rate, the volume of CSF in the ventricles and subarachnoid space is constant. If the apertures of the fourth ventricle or the cerebral aqueduct are blocked, CSF can accumulate within the ventricles. This condition is called **internal hydrocephalus**, or **noncommunicating hydrocephalus**, and it results in increased CSF pressure. The production of CSF continues, even when the passages that normally allow it to exit the brain are blocked. Consequently, fluid builds inside the brain, causing pressure, which compresses the nervous tissue and dilates the ventricles. Compression of the nervous tissue usually results in irreversible brain damage. If the skull bones are not completely ossified when the hydrocephalus occurs, the pressure may also severely enlarge the head. The cerebral aqueduct may be blocked at the time of birth or may become blocked later in life because of a tumor growing in the brainstem. Internal hydrocephalus can be successfully treated by placing a drainage tube (shunt) between the brain ventricles and abdominal cavity to eliminate the high internal pressures. There is some risk of infection being introduced into the brain through these shunts, however, and the shunts must be replaced as the person grows. A subarachnoid hemorrhage may block the return of CSF to the circulation. If CSF accumulates in the subarachnoid space, the condition is called **external hydrocephalus**, or **communicating hydrocephalus**. In this condition, pressure is applied to the brain externally compressing neural tissues and causing brain damage.

### Self-Assessment Exercises

- Differentiate the parts of the ventricular system and relate them to the different regions of the brain.
- Describe the walls of the different parts of the ventricular system.
- Discuss the production and flow of the cerebrospinal fluid.

## Activity

Locate and identify the ventricles, canals and capillary beds associated with the circulation of cerebrospinal fluid on the brain models provided or preserved animal brains in the anatomy laboratory/Museum.

## 4.0 CONCLUSION

The ventricles are cavities within the brain for the production and drainage of Cerebrospinal fluid (CSF). It consists of the lateral ventricles, the 3rd ventricle and the 4th ventricle. The ventricular system of the brain is continuous with the central canal of the spinal cord. The ventricles contain CSF that cushions the brain and spinal cord within its bony container as well as provide nourishment.

## 5.0 SUMMARY

- The lateral ventricles in the cerebrum are connected to the third ventricle in the diencephalon by the interventricular foramina.
- The third ventricle is connected to the fourth ventricle in the pons by the cerebral aqueduct. The central canal of the spinal cord is connected to the fourth ventricle.
- The fourth ventricle is connected to the subarachnoid space by the median and lateral apertures.
- CSF is produced from the blood in the choroid plexus of each ventricle by ependymal cells. CSF moves from the lateral to the third and then to the fourth ventricle. From the fourth ventricle, CSF enters the subarachnoid space through three apertures.
- CSF leaves the subarachnoid space through arachnoid granulations and returns to the blood in the dural venous sinuses.

## 6.0 TUTOR MARKED ASSIGNMENTS

1. Cerebrospinal fluid is produced by the \_\_\_\_\_, circulates through the ventricles, and enters the subarachnoid space. The cerebrospinal fluid leaves the subarachnoid space through the
  - a. choroid plexuses, arachnoid granulations
  - b. arachnoid granulations, choroid plexuses
  - c. dural venous sinuses, dura mater
  - d. dura mater, dural venous sinuses
2. Describe the ventricles of the brain.
3. What are the physical characteristics of CSF?

## 7.0 REFERENCES AND OTHER RESOURCES

Hutchinson, M., Mallat, J., Marieb, E.N., Wilhelm P.B. (2007). A Brief Atlas of the Human Body. Sna Fransisco: Pearson Education Inc.

Katherine M. A. Rogers and William N. Scott (2011) Nurses! Test Yourself in Anatomy and Physiology

Kathryn A. Booth, Terri. D. Wyman (2008) Anatomy, Physiology, and Pathophysiology for Allied Health

Keith L Moore, Persuade T.V.N (2018), The Developing Human Clinically Oriented Embryology 11th Edition Lippincott Williams & Wilkins

Kent M. Van De Graff, R.Ward Rhees, Sidney Palmer (2010) Schaum's Outline of human Anatomy and Physiology 3rd edition.

Philip Tate (2012) Seeley's Principles of Anatomy & Physiology 2nd ed.

Sadler T.W (2012), Langman's Medical Embryology 12th edition.

Seeley's Principles of Anatomy & Physiology, Second edition Published by McGraw-Hill, a business unit of The McGraw-Hill Companies, Inc., 1221 Avenue of the Americas, New York, NY 10020. Copyright c 2012- Chapter 17&18

## **UNIT 7 BLOOD SUPPLY OF THE CENTRAL NERVOUS SYSTEM**

### **CONTENTS**

- 1.0 Introduction
- 2.0 Objective
- 3.0 Main Content
  - 3.1 Internal carotid system
  - 3.2 Vertebral system
  - 3.3 Basilar system
  - 3.4 The Circle of Willis
  - 3.5 Venous drainage
  - 3.6 Clinical correlates
- 4.0 Conclusion
- 5.0 Summary
- 6.0 Tutor Marked Assignments
- 7.0 References and other resources

### **1.0 INTRODUCTION**

The brain requires a tremendous amount of blood to maintain its normal functions. The brain has a very high metabolic rate, and brain cells are not capable of storing high-energy molecules for any length of time. In addition, brain cells depend almost entirely on glucose as their energy source. Thus, the brain requires a constant blood supply to meet the demands of brain cells for both glucose and oxygen. Even though the brain accounts for only about 2% of the total weight of the body, it receives approximately 15%–20% of the blood pumped by the heart. Interruption of the brain's blood supply for only seconds can cause unconsciousness, and interruption of the blood supply for minutes can cause irreversible brain damage.

### **2.0 OBJECTIVE**

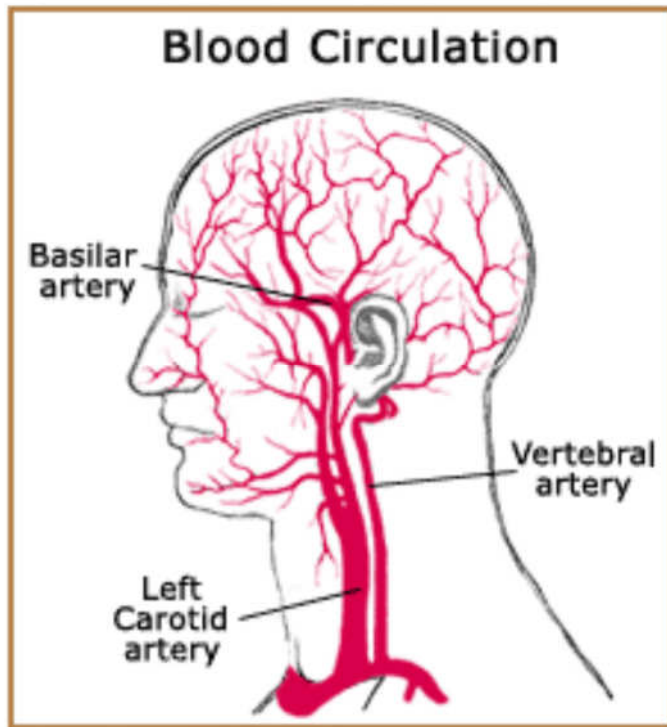
At the end of this unit, you will be able to:

- describe the arterial supply of the brain and the spinal cord.
- describe the venous drainage of the brain and the spinal cord.
- define the blood-brain barrier and its effect on the movement of materials into and out of the brain.

### 3.0 MAIN CONTENT

#### 3.1 Internal carotid system

The main blood supply to the central nervous system include the internal carotid, vertebral and basilar systems of arteries.



The internal carotid system consists of the anterior and middle cerebral arteries, anterior choroidal and posterior communicating arteries. The internal carotid artery proceeds superiorly alongside the optic chiasma, bifurcates into the middle cerebral artery and anterior cerebral artery.

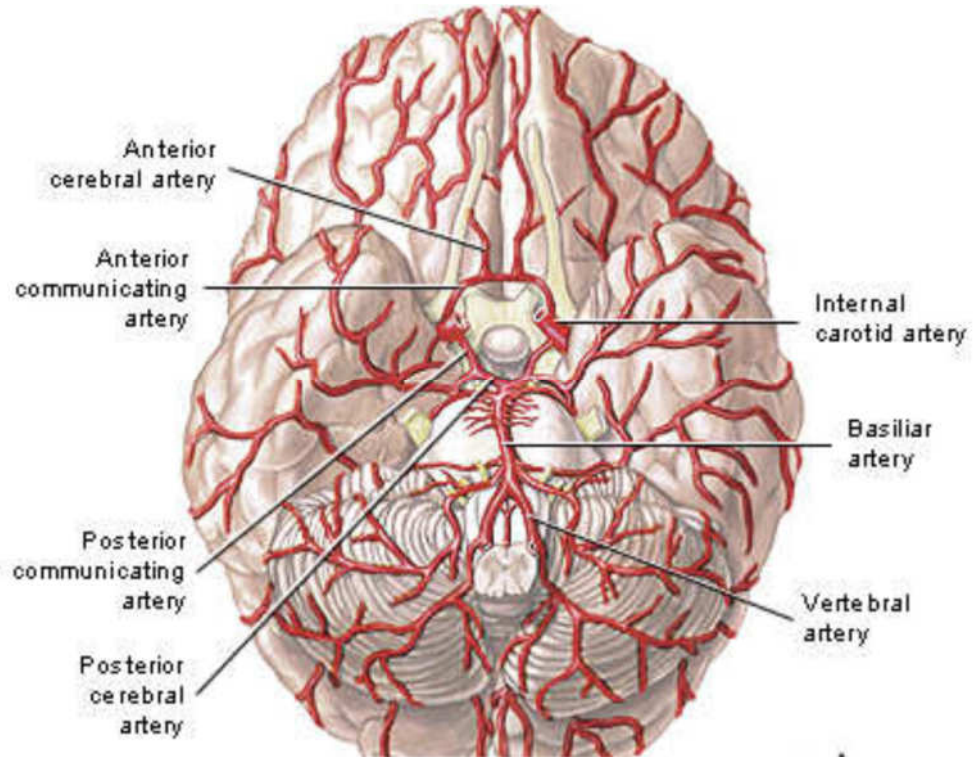
It contributes to the formation of the choroid plexus of the lateral ventricle (especially inferior horn). It gives 2 smaller branches before bifurcating viz; anterior choroidal artery and posterior communicating artery.

**Anterior Choroidal Artery;** It runs posterior to the optic tract, clinically significant, long and thin artery. It is frequently involved in CVA. It supplies:

Optic tract, Lateral geniculate body, Optic radiation, Uncus, Amygdala, Hippocampus, Internal capsule, Lentiform nucleus (globus pallidus and putamen) and Thalamus

**Posterior Communicating Artery;** It runs posterior inferiorly to the optic tract joining the posterior cerebral artery. It participates in the formation of the circle of Willis.

**Anterior Cerebral Artery;** It runs superiorly and medially to the optic nerve to enter the longitudinal fissure.



The two are interconnected by the anterior communicating artery just before entering the longitudinal fissure. It runs posteriorly following the corpus callosum supplying the medial surfaces of frontal and parietal lobes rostral to the parieto-occipital sulcus.

It divides into 2 prominent branches:

**Peri-callosal artery;** adjacent to the corpus callosum.

**Calloso-marginal artery;** which follows the cingulate sulcus.

It supplies the paracentral lobule (medial aspects of the precentral and postcentral gyri), and then its occlusion will cause restricted contralateral motor and somatosensory deficits.

**Middle Cerebral Artery;** runs laterally into the lateral sulcus, supply the insula and temporal pole. Numerous branches spread out from the sulcus to supply the lateral surface of the cerebrum. Its occlusion causes major motor and somatosensory deficits. Also, if the left hemisphere is involved, language deficits are almost invariably found. Deep structures

of diencephalon and telencephalon are supplied by its numerous small branches (lenticulostriate arteries).

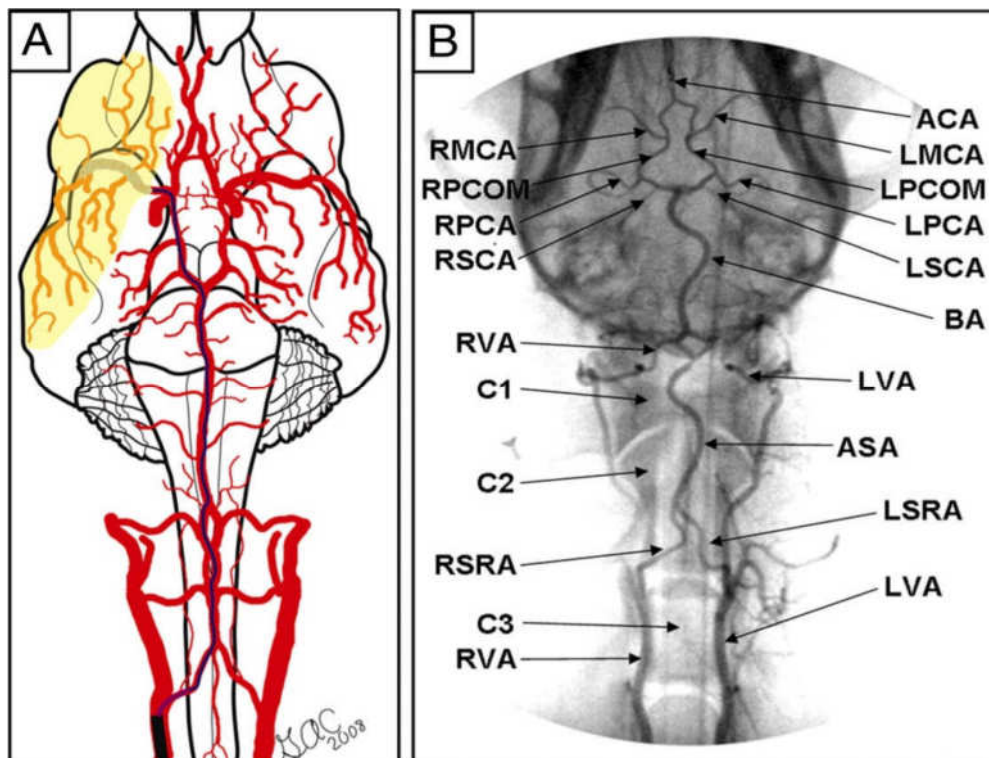
### 3.2 Vertebral system

Vertebral Arteries; they run alongside the medulla, fuse at the pontomedullary junction to form the basilar artery. Before the union it gives 3 branches;

**The posterior spinal artery;** runs along the dorsolateral aspect of SC supplying the dorsal 1/3rd.

**The anterior spinal artery;** join together to form a single anterior spinal artery, run on the antero-medial surface of SC to supply ventral 2/3rd.

**Posterior Inferior Cerebellar Artery (PICA);** approaches the cerebellum to supply its inferior surface. As it curves around the brainstem, the artery supplies the choroid plexus of the 4th ventricle and much of the lateral medulla.

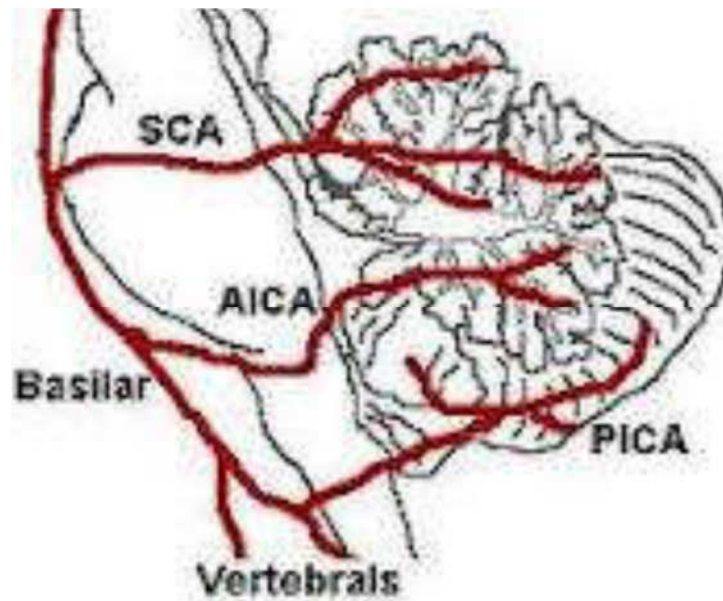


### 3.3 Basilar system

The basilar artery runs in the pontine groove, bifurcates at midbrain level into 2 posterior cerebral arteries. Also give rise to the following; **Anterior inferior cerebellar artery;** formed rostral to formation of



basilar artery, supplies the anterior part of the inferior cerebellar surface and the lower part of pons.



**Superior cerebellar artery;** it is formed just before the bifurcation of basilar artery, supplies the upper part of pons, superior surface of cerebellum and caudal part of midbrain.

**The internal auditory artery;** It supplies the middle ear, occlusion causes vertigo and deafness. Often comes from AICA. Numerous unnamed branches; e.g pontine arteries.

**Posterior Cerebral Artery;** it runs around the midbrain passing through the superior cistern.

It supplies the medial surfaces of the occipital and temporal lobes. Also send branches to the upper part of midbrain and lower part of diencephalon. It also gives rise to several posterior choroidal arteries. Since the primary visual cortex is located in the occipital lobe, occlusion of the posterior cerebral artery could lead to visual loss among other symptoms

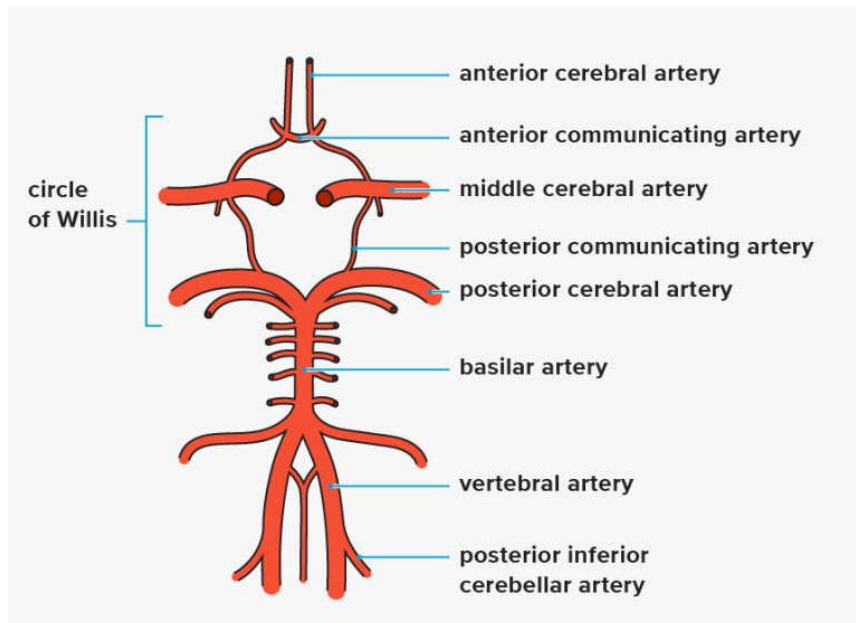
**Posterior Choroidal Arteries;** form the choroid plexus of 3rd and that of body of 4th ventricles.

### 3.4 The Circle of Willis

The posterior cerebral artery is connected to the internal carotid artery by the posterior communicating artery. This completes an arterial polygon called the circle of Willis which allows for anastomotic blood

flow in case of occlusion. Several small arteries arise from the circle which are grouped thus;

**The antero-medial;** supplies the head of caudate, anterior limb of internal capsule and anterior part of hypothalamus.



The circle of willis

**The anterolateral;** also known as lenticulostriate, supplies the internal capsule, globus pallidus, putamen, head of caudate, claustrum and external capsule.

**The posteromedial;** supplies medial part of midbrain, anteriomedial part of thalamus, subthalamic region, middle and posterior part of hypothalamus.

**The posterolateral;** also known as thalamogeniculate artery, supply the posterior part of thalamus and lateral part of midbrain.

### 3.5 Venous drainage

The principal route of venous drainage of the brain is through a system of cerebral veins. These empty into the dura venous sinuses and ultimately into the internal jugular vein. There is also a collection of emissary veins.

These connect the extracranial veins with the dural sinuses. There is a basilar venous plexus around the base of the brain that communicates with the epidural venous plexus of the spinal cord. Cerebral veins are

divided into superficial and deep groups. Generally, the superficial veins lie on the surface of the cerebral hemispheres and empty into the superior sagittal sinus. The deep veins drain internal structures and eventually drain into the straight sinus. Cerebral veins are valve-less. They are also interconnected by numerous functional anastomoses both within a group and between the superficial and deep groups.

### 3.6 Clinical correlates

#### Blood Brain Barrier

- Branches of the arteries supplying the brain are located in the subarachnoid space. Smaller branches from the arteries in the subarachnoid space extend into the brain and quickly divide into capillaries. The epithelial cells of these capillaries are surrounded by the foot processes of astrocytes. The astrocytes promote the formation of tight junctions between the epithelial cells. The epithelial cells with their tight junctions form the blood–brain barrier, which regulates the movement of materials from the blood into the brain.

Materials that would enter many tissues by passing between the epithelial cells of capillaries cannot pass through the blood–brain barrier because of the tight junctions. Most materials that enter the brain pass through the epithelial cells. Lipid-soluble substances, such as nicotine, ethanol, and heroin, can diffuse through the plasma membranes of the epithelial cells and enter the brain. Water-soluble molecules, such as amino acids and glucose, move across the plasma membranes of the epithelial cells by mediated transport.

- ii. The permeability characteristics of the blood–brain barrier must be considered when developing drugs designed to affect the CNS. For example, Parkinson disease is caused by a lack of the neurotransmitter dopamine, which normally is produced by certain neurons of the brain. A lack of dopamine results in decreased muscle control and shaking movements. Administering dopamine is not helpful because dopamine cannot cross the blood–brain barrier. Levodopa (L-dopa), a precursor to dopamine, is administered instead because it can cross the blood–brain barrier. CNS neurons then convert levodopa to dopamine, which helps reduce the symptoms of Parkinson disease.

#### Self-Assessment Exercises

- describe the arterial supply of the brain and the spinal cord.
- describe the venous drainage of the brain and the spinal cord.

- define the blood-brain barrier and its effect on the movement of materials into and out of the brain.

### **Activity**

In the anatomy museum, identify the arterial supplies and venous drainage of the central nervous system.

## **4.0 CONCLUSION**

The brain requires a tremendous amount of blood to maintain its normal functions. The brain has a very high metabolic rate, and brain cells are not capable of storing high-energy molecules for any length of time. In addition, brain cells depend almost entirely on glucose as their energy source. Thus, the brain requires a constant blood supply to meet the demands of brain cells for both glucose and oxygen.

## **5.0 SUMMARY**

- The blood–brain barrier is formed by the endothelial cells of the capillaries in the brain. It limits what substances enter brain tissue.
- The principal route of venous drainage of the brain is through a system of cerebral veins
- The main blood supply to the central nervous system includes the internal carotid, vertebral and basilar systems of arteries.
- The internal carotid system consists of the anterior and middle cerebral arteries, anterior choroidal and posterior communicating arteries
- Vertebral arteries run alongside the medulla, fuse at the pontomedullary junction to form the basilar artery. It has three divisions: anterior spinal, posterior spinal and posterior inferior cerebellar artery.
- The basilar system with several branches.

## **6.0 TUTOR MARKED EXERCISES**

1. Which of the following statements is true?
  - a. The brain requires constant delivery of glucose and oxygen to function.
  - b. The foot processes of astrocytes surround capillaries in the brain.
  - c. Tight junctions between capillary epithelial cells form the blood – brain - barrier.

- d. Glucose passes through capillary epithelial cells by mediated transport.
  - e. all of the above.
2. Discuss the importance of the *blood–brain barrier* in maintaining homeostasis within the brain.
  3. *True or false:* Alcohol passes readily through the BBB because it is a lipid-soluble compound.
  4. Discuss the circle of willis.
  5. Discuss the venous drainage of the central nervous system.

## 7.0 REFERENCES AND OTHER RESOURCES

Hutchinson, M., Mallat, J., Marieb, E.N., Wilhelm P.B. (2007). A Brief Atlas of the Human Body. Sna Franciscano: Pearson Education Inc.

Katherine M. A. Rogers and William N. Scott (2011) Nurses! Test Yourself in Anatomy and Physiology

Kathryn A. Booth, Terri. D. Wyman (2008) Anatomy, Physiology, and Pathophysiology for Allied Health

Keith L Moore, Persuade T.V.N (2018), The Developing Human Clinically Oriented Embryology 11th Edition Lippincott Williams & Wilkins

Kent M. Van De Graff, R.Ward Rhees, Sidney Palmer (2010) Schaum’s Outline of human Anatomy and Physiology 3rd edition.

Philip Tate (2012) Seeley’s Principles of Anatomy & Physiology 2nd ed.

Sadler T.W (2012), Langman’s Medical Embryology 12th edition.

Seeley’s Principles of Anatomy & Physiology, Second edition Published by McGraw-Hill, a business unit of The McGraw-Hill Companies, Inc., 1221 Avenue of the Americas, New York, NY 10020. Copyright c 2012- Chapter 17&18

## MODULE 3 THE PERIPHERAL AND AUTONOMIC NERVOUS SYSTEM

### INTRODUCTION

Anatomically, the nervous system is divided into the **central nervous system (CNS)** and the **peripheral nervous system (PNS)**. The CNS includes the *brain* and the *spinal cord* (see previous module). The PNS (described in this module) includes the *cranial nerves*, arising from the inferior aspect of the brain, and the *spinal nerves*, arising from the spinal cord.

The **autonomic nervous system (ANS)** is a functional division of the nervous system. It consists of components within the CNS and specific nerves. The ANS is subdivided into *sympathetic* and *parasympathetic divisions* that provide innervation to smooth and cardiac muscles, as well as glands. The ANS functions autonomically to maintain homeostasis and carry out many involuntary functions in the body. The peripheral nervous system consists of nerves that branch off the CNS. These nerves are called peripheral nerves and are classified in two types, **cranial nerves** and **spinal nerves**.

### 2.0 OBJECTIVE

At the end of this module, you should be able to:

- Differentiate between structural and functional divisions of the nervous system.
- Discuss the peripheral and autonomic nervous systems

### CONTENT

|        |                          |
|--------|--------------------------|
| Unit 1 | Cranial nerves           |
| Unit 2 | Spinal nerves            |
| Unit 3 | Autonomic nervous system |

### UNIT 1 CRANIAL NERVES

#### CONTENT

- 1.0 Introduction
- 2.0 Objectives
- 3.0 Main content
  - 3.1 Names and function
  - 3.2 Trigeminal nerve and dental anesthesia
  - 3.3 Brain stem reflexes

- 3.4 Clinical correlates
- 4.0 Conclusion
- 5.0 Summary
- 6.0 Tutor Marked Assignments
- 7.0 References and other resources

## 1.0 INTRODUCTION

Cranial nerves are peripheral nerves that originate from the brain. Roman numerals and names designate the twelve different cranial nerves. The cranial nerves also have names in numeric order, this mnemonic can help you remember their names:

**On Occasion Our Trusty Truck Acts Funny; Very Good Vehicle Any How.** The mnemonic corresponds to the **O**lfactory (I), **O**ptic (II), **O**culomotor (III), **T**rochlear (IV), **T**rigeminal (V), **A**bducent (VI), **F**acial (VII), **V**estibulocochlear (VIII), **G**lossopharyngeal (IX), **V**agus (X), **A**ccessory (XI), and **H**ypoglossal (XII) nerves

## 2.0 OBJECTIVES

At the end of this unit, you will be able to:

- Discuss the distribution and function of each of the cranial nerves
- Discuss the brain stem reflexes

## 3.0 MAIN CONTENT

### 3.1 Names and function

- *Olfactory nerves* carry smell information to the brain for interpretation.
- *Optic nerves* carry visual information to the brain for interpretation.
- *Oculomotor nerves* are found within the muscles that move the eyeball, eyelid, and iris.
- *Trochlear nerves* act in the muscles that move the eyeball.
- *Trigeminal nerves* carry sensory information from the surface of the eye, the scalp, facial skin, the lining of the gums, and the palate to the brain for interpretation. They also are found within the muscles needed for chewing.

- *Abducens nerves* act in the muscles that move the eyeball.
- *Facial nerves* are found in the muscles of facial expression as well as in the salivary and tear glands. These nerves also carry sensory information from the tongue.
- *Vestibulocochlear nerves* carry hearing and equilibrium information from the inner ear to the brain for interpretation.
- *Glossopharyngeal nerves* carry sensory information from the throat and tongue to the brain for interpretation. They also act in the muscles of the throat.
- *Vagus nerves* carry sensory information from the thoracic and abdominal organs to the brain for interpretation. These nerves are also found within the muscles in the throat, stomach, intestines, and heart.
- *Accessory nerves* are found within the muscles of the throat, neck, back, and voice box.
- *Hypoglossal nerves* are found within the muscles of the tongue.

### 3.2 Trigeminal nerve and dental anesthesia

*Trigeminal* means three twins, and the sensory distribution of the trigeminal nerve in the face is divided into three regions, each supplied by a branch of the nerve. The three branches, **ophthalmic**, **maxillary**, and **mandibular**—arise directly from the trigeminal ganglion, which serves the same function as the dorsal root ganglia of the spinal nerves. Only the mandibular branch contains motor axons, which bypass the trigeminal ganglion, much as the ventral root of a spinal nerve bypasses a dorsal root ganglion.

The maxillary and mandibular branches are important in dentistry. The maxillary nerve supplies sensory innervation to the maxillary teeth, palate, and gingiva. The mandibular branch supplies sensory innervation to the mandibular teeth, tongue, and gingiva. The various nerves innervating the teeth are referred to as **alveolar nerves**. The **superior alveolar nerves** to the maxillary teeth are derived from the maxillary branch of the trigeminal nerve, and the **inferior alveolar nerves** to the mandibular teeth are derived from the mandibular branch of the trigeminal nerve.



Dentists inject anesthetic to block sensory transmission by the alveolar nerves. The superior alveolar nerves are not usually anesthetized directly because they are difficult to approach with a needle. For this reason, the maxillary teeth are usually anesthetized locally by inserting the needle beneath the oral mucosa surrounding the teeth. The inferior alveolar nerve probably is anesthetized more often than any other nerve in the body. To anesthetize this nerve, the dentist inserts the needle somewhat posterior to the patient's last molar and extends the needle near where the mandibular branch of the trigeminal nerve enters the mandibular foramen. Several nondental nerves are usually anesthetized during an inferior alveolar block. The mental nerve, which supplies cutaneous innervation to the anterior lip and chin, is a distal branch of the inferior alveolar nerve. When the inferior alveolar nerve is blocked, the mental nerve is blocked also, resulting in a numb lip and chin. Nerves lying near the point where the inferior alveolar nerve enters the mandible often are also anesthetized during inferior alveolar anesthesia. For example, the lingual nerve can be anesthetized to produce a numb tongue. The facial nerve lies some distance from the inferior alveolar nerve, but in rare cases anesthetic can diffuse far enough posteriorly to anesthetize that nerve. The result is a temporary facial palsy, with the injected side of the face drooping because of flaccid muscles, which disappears when the anesthesia wears off. If the facial nerve is cut by an improperly inserted needle, permanent facial palsy may occur.

### **3.3 Brain stem reflexes**

Many of the brainstem reflexes are associated with cranial nerve function. The circuitry of most of these reflexes is too complex for our discussions. In general, these reflexes involve sensory input from the cranial nerves or spinal cord, as well as the motor output of the cranial nerves. Turning of the eyes toward a flash of light, a sudden noise, and a touch on the skin are examples of brainstem reflexes. Moving the eyes to track a moving object is another complex brainstem reflex. Some of the sensory neurons from cranial nerve VIII (vestibulocochlear) form a reflex arc with neurons of cranial nerves V (trigeminal) and VII (facial), which send axons to muscles of the middle ear and dampen the effects of very loud, sustained noises on delicate inner ear structures. Reflexes that occur during the process of chewing allow the jaws to react to foods of various hardness and protect the teeth from breakage. Both the sensory and motor components of the reflex arc are carried by cranial nerve V (trigeminal). Reflexes involving input through cranial nerve V (trigeminal) and output through cranial nerve XII (hypoglossal) move the tongue about to position food between the teeth for chewing and then move the tongue out of the way so that it is not bitten.

Brainstem reflexes are used to determine if the brainstem is functioning. Brainstem reflexes are mediated by cranial nerve sensory nuclei, cranial nerve motor nuclei, and reticular formation nuclei. The presence of a reflex indicates that sensory input reaches the brainstem and the nuclei are functioning to produce a response. The absence of a reflex is taken to indicate damage to the nuclei involved in the reflex.

### 3.4 Clinical correlates

#### Cranial Nerve Disorders

Trigeminal neuralgia, also called tic douloureux, involves the trigeminal nerve and consists of sharp bursts of pain in the face. This disorder often has a trigger point in or around the mouth, which, when touched, elicits the pain response in some other part of the face. The cause of trigeminal neuralgia is unknown. Facial palsy (called Bell palsy) is a unilateral paralysis of the facial muscles. The affected side of the face droops because of the absence of muscle tone. Although the cause of facial palsy is often unknown, it can result from inflammation of the facial nerve or a stroke or tumor in the cerebral cortex or brainstem. The facial nerve passes from deep to superficial through the parotid gland, and temporary facial palsy can result from inflammation of the parotid gland. Temporary facial palsy can even result from extreme cold in the face, where the superficial branches of the facial nerve are located.

**Disorders of the cranial nerves can be determined using the following tests:**

- The olfactory nerves (I) are tested by asking a patient to smell various substances.
- Cranial nerves III, IV, and VI are tested by asking a patient to track the movement of the physician's finger. If a patient cannot move her eyeballs properly, there may be damage to one of these nerves. Recall that these nerves control the muscles that move the eyeballs.
- Cranial nerve V controls the muscles needed for chewing. To assess this nerve, a patient is asked to clench his teeth. The physician then feels the jaw muscles. If they feel limp or weak, this nerve may be damaged.
- If a person can no longer make facial expressions, then cranial nerve VII may be damaged. This nerve controls the muscles needed to make facial expressions.

- If a patient cannot extend his tongue and move it from side to side, cranial nerve XII may be damaged. This nerve controls tongue movement.

### **Self-Assessment Exercises**

- Discuss the distribution and function of each of the cranial nerves
- Discuss the brain stem reflexes

## **4.0 CONCLUSION**

Cranial nerves are designated by Roman numerals (I–XII) or specific names.

## **5.0 SUMMARY**

- The two types of general functions are sensory and motor. Sensory includes special senses and general senses. Motor includes somatic motor and parasympathetic.
- The trigeminal nerve (V) has three branches—ophthalmic, maxillary, and mandibular. The superior alveolar nerve (branch of the maxillary) and the inferior alveolar nerve (branch of the mandibular) are used for dental anesthesia.
- Many reflexes are mediated through the brainstem. The brainstem is considered to be non-functional when reflexes at all levels of the brainstem are non-functional and there is no spontaneous breathing, which is mediated through the medulla oblongata

## **6.0 TUTOR MARKED ASSIGNMENTS**

1. The cranial nerve involved in chewing food is the
  - a. trochlear (IV).
  - b. trigeminal (V).
  - c. abducent (VI).
  - d. facial (VII).
  - e. vestibulocochlear (VIII).
  
2. The cranial nerve involved in moving the tongue is the
  - a. trigeminal (V).
  - b. facial (VII).
  - c. glossopharyngeal (IX).
  - d. accessory (XI).

- e. hypoglossal (XII).
3. The cranial nerve involved in feeling a toothache is the
- a. trochlear (IV).
  - b. trigeminal (V).
  - c. abducent (VI).
  - d. facial (VII).
  - e. vestibulocochlear (VIII).
4. From this list of cranial nerves:
- 1. optic (II)
  - 2. oculomotor (III)
  - 3. trochlear (IV)
  - 4. trigeminal (V)
  - 5. abducent (VI)

Select the nerves that are involved in moving the eyes.

- a. 1,2,3
- b. 1,2,4
- c. 2,3,4
- d. 2,4,5
- e. 2,3,5

5. From this list of cranial nerves:

- 1. trigeminal (V)
- 2. facial (VII)
- 3. glossopharyngeal (IX)
- 4. vagus (X)
- 5. hypoglossal (XII)

Select the nerves that innervate the salivary glands.

- a. 1,2
- b. 2,3
- c. 3,4
- d. 4,5
- e. 3,5

6. From this list of cranial nerves:

- 1. oculomotor (III)
- 2. trigeminal (V)
- 3. facial (VII)
- 4. vestibulocochlear (VIII)

5. glossopharyngeal (IX)
6. vagus (X)
7. Where do the cranial nerves attach to the brain?
8. Of all the cranial nerves, which is most important to a dentist?

## **7.0 REFERENCES AND OTHER RESOURCES**

Hutchinson, M., Mallat, J., Marieb, E.N., Wilhelm P.B. (2007). A Brief Atlas of the Human Body. Sna Francisco: Pearson Education Inc.

Katherine M. A. Rogers and William N. Scott (2011) Nurses! Test Yourself in Anatomy and Physiology

Kathryn A. Booth, Terri. D. Wyman (2008) Anatomy, Physiology, and Pathophysiology for Allied Health

Keith L Moore, Persuade T.V.N (2018), The Developing Human Clinically Oriented Embryology 11th Edition Lippincott Williams & Wilkins

Kent M. Van De Graff, R.Ward Rhees, Sidney Palmer (2010) Schaum's Outline of human Anatomy and Physiology 3rd edition.

Philip Tate (2012) Seeley's Principles of Anatomy & Physiology 2nd ed.

Sadler T.W (2012), Langman's Medical Embryology 12th edition.

Seeley's Principles of Anatomy & Physiology, Second edition Published by McGraw-Hill, a business unit of The McGraw-Hill Companies, Inc., 1221 Avenue of the Americas, New York, NY 10020. Copyright c 2012- Chapter 17&18

## UNIT 2 SPINAL NERVES

### CONTENTS

- 1.0 Introduction
- 2.0 Objectives
- 3.0 Main Content
  - 3.1 Structure of nerves
  - 3.2 Distribution of nerves
  - 3.3 Major nerve plexuses
  - 3.4 Clinical correlates
- 4.0 Conclusion
- 5.0 Summary
- 6.0 Tutor Marked Assignments
- 7.0 References and other resources

### 1.0 INTRODUCTION

Spinal nerves are peripheral nerves that originate from the spinal cord. There are 31 pairs of spinal nerves: 8 pairs of cervical nerves (numbered C1 through C8), 12 pairs of thoracic nerves (numbered T1 through T12), 5 pairs of lumbar nerves (numbered L1 through L5), 5 pairs of sacral nerves (numbered S1 through S5), and one pair of coccygeal nerves (Co).

### 2.0 OBJECTIVES

At the end of this unit, you should be able to:

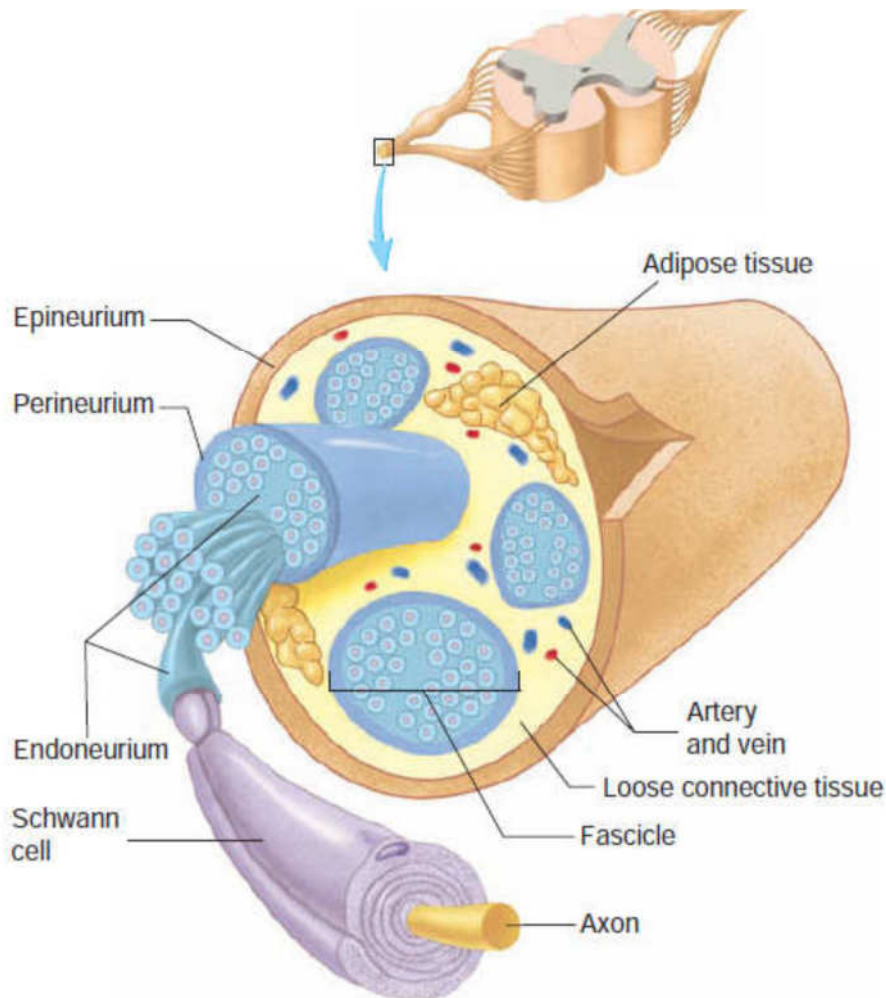
- Locate and describe the spinal nerves.
- Discuss the spinal *reflex arc*.

### 3.0 MAIN CONTENT

#### 3.1 Structure of nerves

Nerves consist of collections of axons, Schwann cells, and connective tissue in the PNS. Each axon, or nerve fiber, and its Schwann cell sheath are surrounded by a delicate connective tissue layer, the endoneurium. A heavier connective tissue layer, the perineurium, surrounds groups of axons to form nerve fascicles. A third layer of dense connective tissue, the epineurium, binds the nerve fascicles together to form a nerve. The connective tissue of the epineurium is continuous with the dura mater surrounding the CNS. An analogy of this relationship is a coat (the dura)

and its sleeve (epineurium). The connective tissue layers of nerves make them tougher than the nerve tracts in the CNS.



## Structure of a nerve

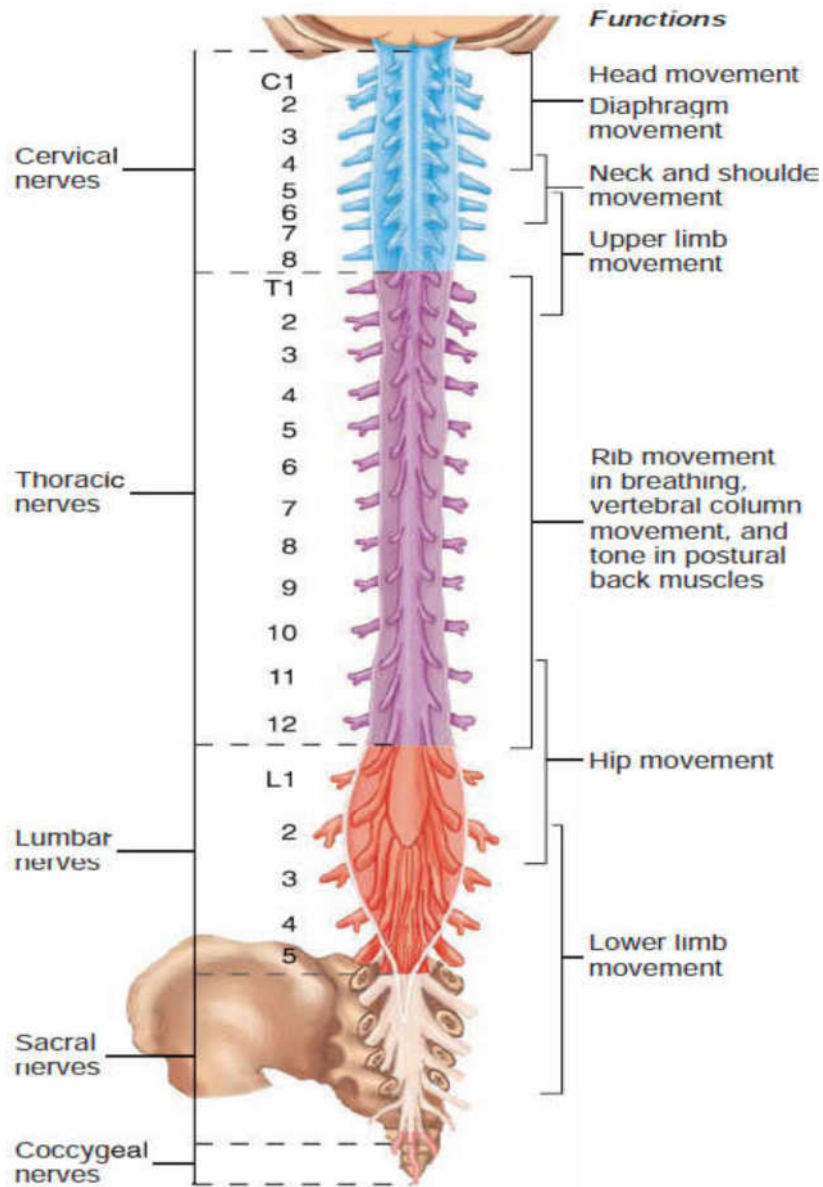
### 3.2 Distribution of nerves

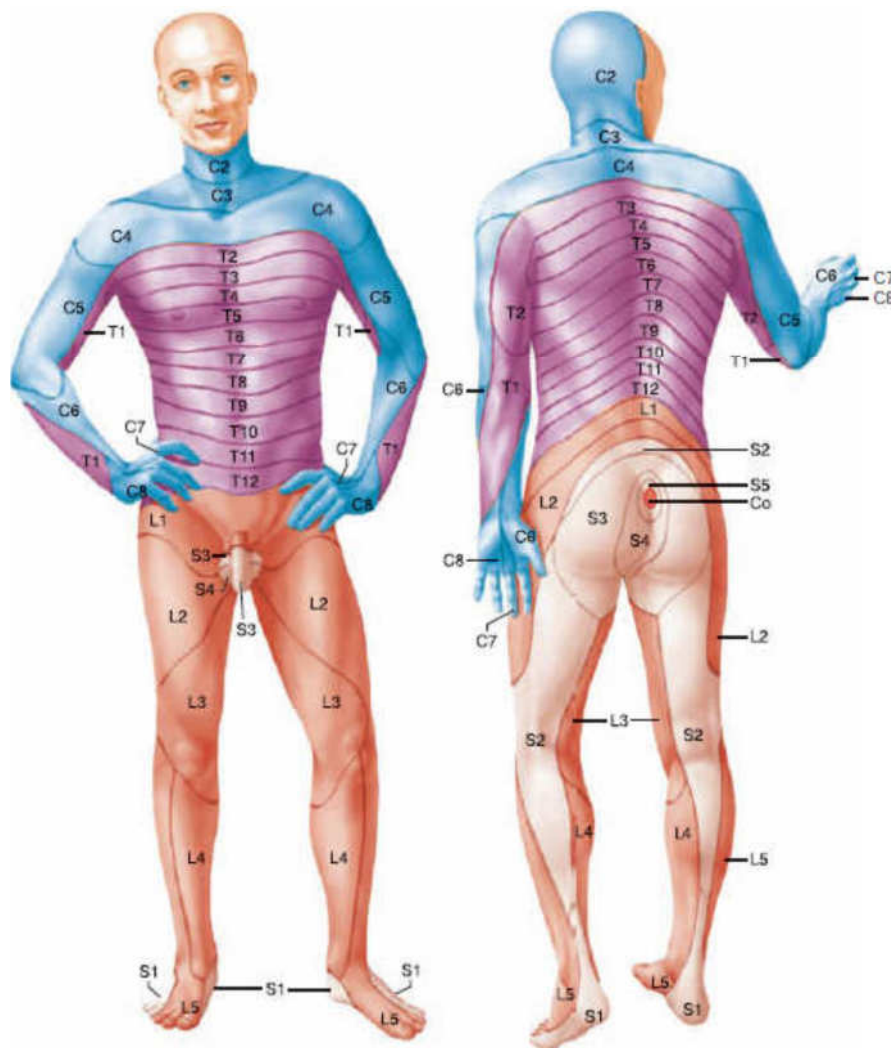
There are 31 pairs of spinal nerves, each identified by a letter and a number. The letter indicates the region of the vertebral column from which the nerve emerges: C, cervical; T, thoracic; L, lumbar; and S, sacral. The single coccygeal nerve may be identified as Co, but typically receives no designation. The number indicates the location in each region where the nerve emerges from the vertebral column, with the smallest number always representing the most superior origin. For example, the most superior nerve exiting from the thoracic region of the vertebral column is designated T1. The cervical nerves are designated C1–C8, the thoracic nerves T1–T12, the lumbar nerves L1–L5, and the sacral nerves S1–S5. Note that the number of each type of nerve matches the number of each type of vertebrae, except for the cervical nerves. Although there are only 7 cervical vertebrae, there are 8 pairs of

cervical spinal nerves because 2 pairs of nerves are associated with the first cervical vertebra. The first pair of cervical nerves exit the spinal cord between the skull and the first cervical vertebra and the second pair exit through the intervertebral foramina between the first and second cervical vertebrae. The nerves arising from each region of the spinal cord and vertebral column supply specific regions of the body. Not surprisingly, the nerves supply skeletal muscles in a top to bottom pattern: the cervical nerves supply muscles of the head, neck, shoulders, and upper limbs; the thoracic nerves supply muscles of the upper limbs, thorax, vertebral column, and hips; the lumbar nerves supply muscles of the vertebral column, hips, and lower limbs; and the sacral nerves supply muscles of the lower limbs.

Each of the spinal nerves except C1 has a specific cutaneous sensory distribution. A **dermatome** is the area of skin supplied with sensory innervation by a pair of spinal nerves. A **dermatomal map** shows the distribution of all the dermatomes.







Dermatomes of the skin

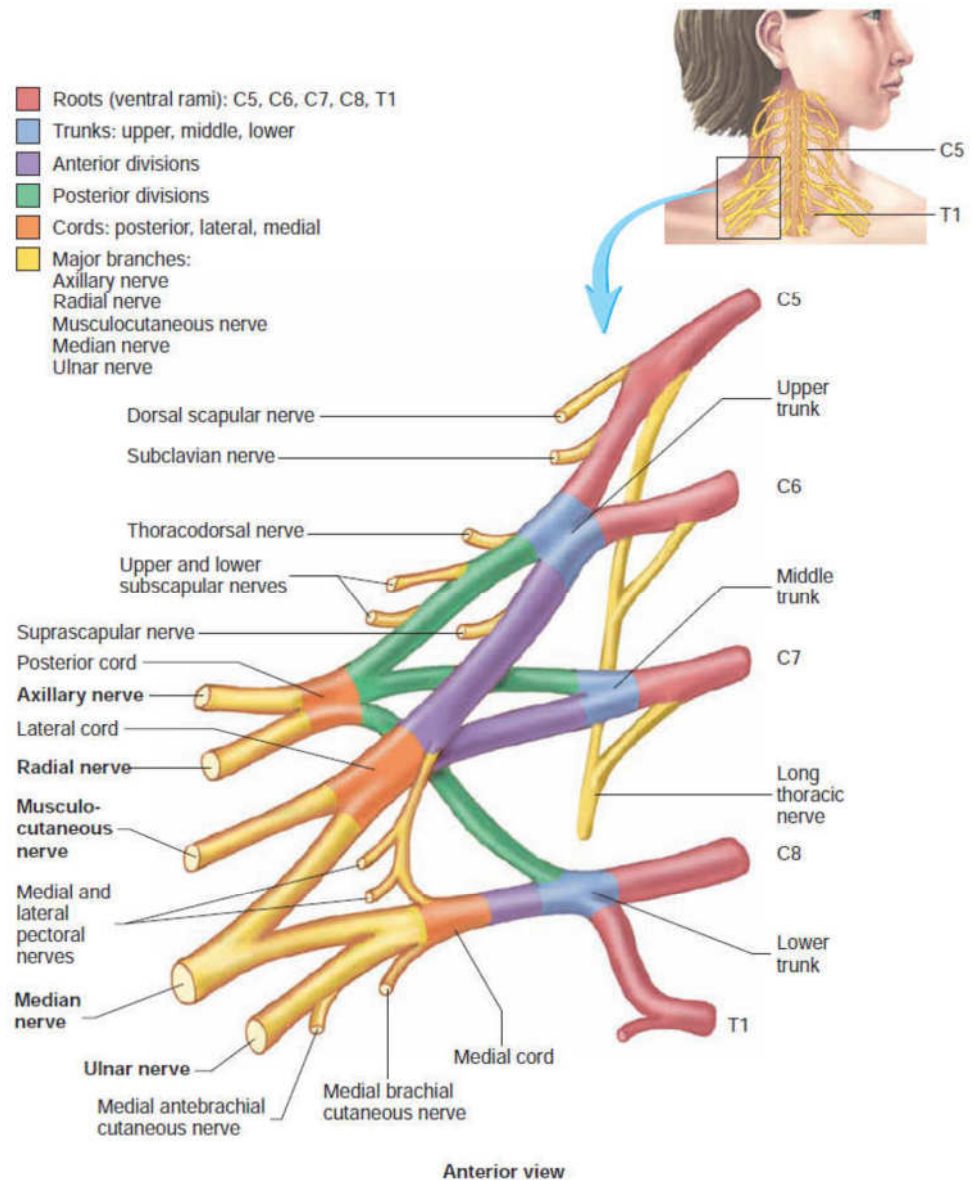
### 3.3 Major nerve plexuses

Spinal nerves arise from the spinal cord as rootlets. The rootlets combine to form the ventral and dorsal roots, which combine to form the spinal nerve. The spinal nerve divides to form branches called rami. Each spinal nerve has a dorsal and a ventral ramus. Additional communicating rami are associated with the sympathetic division of the ANS. The dorsal rami innervate most of the deep muscles of the dorsal trunk responsible for movement of the vertebral column. They also innervate the connective tissue and skin near the midline of the back. The ventral rami are distributed in two ways. In the thoracic region, the ventral rami form intercostal (between ribs) nerves, which extend along the inferior margin of each rib and innervate the intercostal muscles and the skin over the thorax. The ventral rami of the cervical, lumbar, sacral, and coccygeal spinal nerves form plexuses. The term *plexus* means braid and describes the organization produced by the intermingling of the nerves. The brachial plexus will be used to illustrate how the spinal nerves intermingle within a plexus and then give rise to nerves that are

distributed throughout the body. The brachial plexus is the most complicated plexus, and other plexuses have similar, but simpler, interconnections.

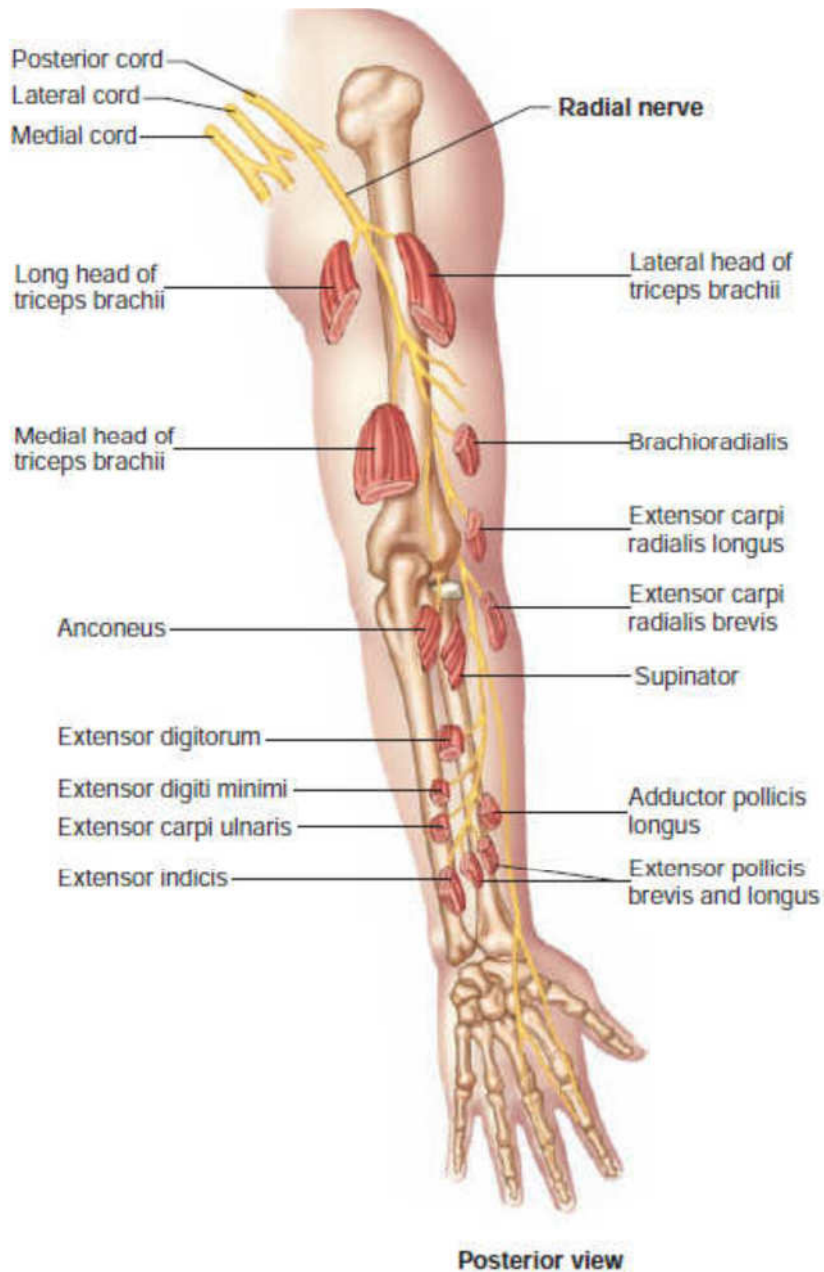
**Brachial plexus**

The brachial plexus originates from spinal nerves C5–T1. The ventral rami of the spinal nerves are called the roots of the plexus. These roots should not be confused with the dorsal and ventral roots from the spinal cord, which are more medial. The five roots join to form three trunks, which separate into six divisions and then join again to create three cords (posterior, lateral, and medial) from which five major **branches**, or nerves, emerge. The five major nerves are the **axillary, radial, musculocutaneous, ulnar, and median nerves**. They supply the upper limb.



### *The brachial plexus*

The distribution of the radial nerve to skeletal muscles of the upper limb is shown below.



### *The radial nerve*

In a similar fashion, nerves arising from plexuses are distributed to skeletal muscles throughout the body. Nerves arising from plexuses also supply the skin. Note that axons of spinal nerves C5–T1 can reach the radial nerve through the interconnections of the brachial plexus. Thus,

axons in the radial nerve arise from levels C5–T1 of the spinal cord. The cutaneous distribution of a nerve arising from a plexus is different from the cutaneous distribution (dermatome) arising from a spinal nerve because the plexus nerve consists of axons from more than one level of the spinal cord.

### **Cervical Plexus**

The **cervical plexus** is a relatively small plexus originating from spinal nerves C1–C4. Branches derived from this plexus innervate superficial neck structures, including several of the muscles attached to the hyoid bone. The cervical plexus innervates the skin of the neck and posterior portion of the head. The **phrenic nerve**, which originates from spinal nerves C3–C5, is derived from both the cervical and brachial plexus. The phrenic nerves descend along each side of the neck to enter the thorax. They descend along the sides of the mediastinum to reach the diaphragm, which they innervate. Contraction of the diaphragm is largely responsible for the ability to breathe.

### **Lumbar and Sacral Plexuses**

The **lumbar plexus** originates from the ventral rami of spinal nerves L1–L4 and the **sacral plexus** from L4 to S4. Because of their close, overlapping relationship and their similar distribution, however, the two plexuses often are considered together as a single **lumbosacral plexus** (L1–S4). Four major nerves exit the lumbosacral plexus and enter the lower limb: the **obturator, femoral, tibial, and common fibular (peroneal) nerves**. Other lumbosacral nerves supply muscles of the lower back, hip, and lower abdomen and the skin of the hip and thigh. The tibial and common fibular nerves originate from spinal segments L4–S3 and are bound together within a connective tissue sheath for the length of the thigh. The two nerves bound together are referred to jointly as the **sciatic nerve**. The sciatic nerve is by far the largest peripheral nerve in the body. It passes through the greater sciatic notch in the coxal bone and descends in the posterior thigh to the back of the knee, where the tibial and common fibular nerves separate from each other. The sciatic nerve supplies the posterior thigh muscles, the tibial nerve supplies the posterior compartment of the leg, and the common fibular supplies the anterior and lateral compartments. Branches of the two nerves combine to form the **sural nerve**, which supplies the skin on the posterior and lateral leg.

### **Coccygeal Plexus**

The **coccygeal plexus** is a very small plexus formed from the ventral rami of spinal nerve S5 and the coccygeal nerve (Co). This small plexus

supplies the muscles of the pelvic floor and the skin over the coccyx. The dorsal rami of the coccygeal nerves also innervate some skin over the coccyx.

### 3.4 Clinical correlates

#### Radial Nerve Damage

The radial nerve lies near the humerus in the axilla. When crutches are used improperly, the crutch is pushed tightly into the axilla. This can damage the radial nerve by compressing it against the humerus, resulting in **crutch paralysis**. In this disorder, muscles innervated by the radial nerve lose their function. The major symptom of radial nerve damage is **wrist drop**, an inability to extend the wrist when the pronated forearm is held parallel to the ground. Consequently, the wrist drops into a flexed position. The radial nerve can be permanently damaged by a fracture of the humerus in the proximal part of the arm. A sharp edge of the broken bone may cut the nerve, resulting in permanent paralysis unless the nerve is surgically repaired. Because of potential damage to the radial nerve, a broken humerus should be treated very carefully.

#### Ulnar Nerve Damage

The ulnar nerve is the most easily damaged of all the peripheral nerves, but such damage is almost always temporary. Slight damage to the ulnar nerve may occur where it passes posterior to the medial epicondyle of the humerus. The nerve can be felt just below the skin at this point, and, if this region of the elbow is banged against a hard object, temporary ulnar nerve damage may occur. This damage results in painful tingling sensations radiating down the ulnar side of the forearm and hand. Because of this sensation, this area of the elbow is often called the **funny bone** or **crazy bone**.

#### Median Nerve Damage

Damage to the median nerve occurs most commonly where it enters the wrist through the **carpal tunnel**. This tunnel is created by the concave organization of the carpal bones and the retinaculum on the anterior surface of the wrist. None of the connective tissue components of the carpal tunnel expand readily. The tendons passing through the carpal tunnel may become inflamed and enlarged as a result of repetitive movements. This inflammation can produce pressure within the carpal tunnel, thereby compressing the median nerve and resulting in numbness, tingling, and pain in the fingers. The thenar muscles, innervated by the median nerve, have reduced function, resulting in weakness in thumb flexion and opposition. This condition is referred to

as **carpal tunnel syndrome**. Carpal tunnel syndrome is common among people who perform repetitive movements of the wrists and fingers, such as keyboard operators. Surgery is often required to relieve the pressure.

### Self-Assessment Exercises

- Describe the spinal nerves.
- Discuss the spinal *reflex arc*.

### Activity

- In the histology laboratory, observe and recognize the microscopic slides of a nerve and its connective tissue coverings.
- In the gross anatomy laboratory/ dissection room, identify the major spinal nerve plexuses – cervical, brachial, lumbar and sacral plexuses.

## 4.0 CONCLUSION

The five major plexuses are the cervical (C1–C4), brachial (C5– T1), lumbar (L1–L4), sacral (L4–S4), and coccygeal (S5 and coccygeal nerve). The lumbar and sacral plexuses are often considered together as the lumbosacral plexus. A major nerve of the cervical plexus is the phrenic nerve. The major nerves of the brachial plexus are the axillary, radial, musculocutaneous, ulnar, and median nerves.

## 5.0 SUMMARY

- Individual axons are surrounded by the endoneurium. Groups of axons, called fascicles, are bound together by the perineurium. The fascicles form the nerve and are held together by the epineurium.
- Eight cervical, 12 thoracic, 5 lumbar, 5 sacral pairs, and 1 coccygeal pair make up the spinal nerves. The distribution of spinal nerves to skeletal muscles has a top-to bottom pattern in which superior nerves supply superior muscles and inferior nerves supply inferior muscles.
- Spinal nerves have specific cutaneous distributions called dermatomes. Spinal nerves branch to form rami. The dorsal rami supply the muscles and skin near the midline of the back.

## 6.0 TUTOR MARKED ASSIGNMENTS

1. Which of these is a correct count of the spinal nerves?
  - a. 9 cervical, 12 thoracic, 5 lumbar, 5 sacral, 1 coccygeal
  - b. 8 cervical, 12 thoracic, 5 lumbar, 5 sacral, 1 coccygeal
  - c. 7 cervical, 12 thoracic, 5 lumbar, 5 sacral, 1 coccygeal
  - d. 8 cervical, 11 thoracic, 4 lumbar, 6 sacral, 1 coccygeal
  - e. 7 cervical, 11 thoracic, 5 lumbar, 6 sacral, 1 coccygeal
  
2. Given these structures:
  1. dorsal ramus
  2. dorsal root
  3. plexus
  4. ventral ramus
  5. ventral root

Choose the arrangement that lists the structures in the order that an action potential passes through them, given that the action potential originates in the spinal cord and propagates to a peripheral nerve.

- a. 2,1,3
  - b. 2,3,1
  - c. 3,4,5
  - d. 5,3,4
  - e. 5,4,3
- 
3. Damage to the dorsal ramus of a spinal nerve results in
    - a. loss of sensation.
    - b. loss of motor function.
    - c. both a and b.
  
  4. A dermatome
    - a. is the area of skin supplied by a pair of spinal nerves.
    - b. exists for each spinal nerve except C1.
    - c. can be used to locate the site of spinal cord or nerve root damage.
    - d. all of the above.
  
  5. A collection of spinal nerves that join together after leaving the spinal cord is called a
    - a. ganglion.
    - b. nucleus.
    - c. projection nerve.
    - d. plexus.



6. Which of these nerves arises from the cervical plexus?
- median
  - musculocutaneous
  - phrenic
  - obturator
  - ulnar sheath.
7. The sciatic nerve is actually two nerves combined within the same. The two nerves are the
- femoral and obturator.
  - femoral and gluteal.
  - common fibular (peroneal) and tibial.
  - common fibular (peroneal) and obturator.
  - tibial and gluteal.

## 7.0 References and other resources

Hutchinson, M., Mallat, J., Marieb, E.N., Wilhelm P.B. (2007). A Brief Atlas of the Human Body. Sna Franscisco: Pearson Education Inc.

Katherine M. A. Rogers and William N. Scott (2011) Nurses! Test Yourself in Anatomy and Physiology

Kathryn A. Booth, Terri. D. Wyman (2008) Anatomy, Physiology, and Pathophysiology for Allied Health

Keith L Moore, Persuade T.V.N (2018), The Developing Human Clinically Oriented Embryology 11th Edition Lippincott Williams & Wilkins

Kent M. Van De Graff, R.Ward Rhees, Sidney Palmer (2010) Schaum's Outline of human Anatomy and Physiology 3rd edition.

Philip Tate (2012) Seeley's Principles of Anatomy & Physiology 2nd ed.

Sadler T.W (2012), Langman's Medical Embryology 12th edition.

Seeley's Principles of Anatomy & Physiology, Second edition Published by McGraw-Hill, a business unit of The McGraw-Hill Companies, Inc., 1221 Avenue of the Americas, New York, NY 10020. Copyright c 2012- Chapter 17&18

## **UNIT 3     AUTONOMIC NERVOUS SYSTEM**

### **CONTENTS**

- 1.0 Introduction
- 2.0 Objectives
- 3.0 Main Content
  - 3.1 Difference between PNS and ANS
  - 3.2 Anatomy of the ANS
  - 3.3 Sympathetic Division
  - 3.4 Parasympathetic Division
  - 3.5 Physiology of ANS
  - 3.6 Receptors
  - 3.7 Regulation of
  - 3.8 Clinical correlates
- 4.0 Conclusion
- 5.0 Summary
- 6.0 Tutor Marked Assignments
- 7.0 References and other resources

### **1.0 INTRODUCTION**

During a picnic on a sunny spring day, it is easy to concentrate on the delicious food and the pleasant surroundings. The maintenance of homeostasis requires no conscious thought. The autonomic nervous system (ANS) helps keep body temperature at a constant level by controlling the activity of sweat glands and the amount of blood flowing through the skin. The ANS helps regulate the complex activities necessary for the digestion of food. The movement of absorbed nutrients to tissues is possible because the ANS controls heart rate, which helps maintain the blood pressure necessary to deliver blood to tissues. Without the ANS, all of the activities necessary to maintain homeostasis would be overwhelming.

A functional knowledge of the ANS enables you to predict general responses to a variety of stimuli, explain responses to changes in environmental conditions, comprehend symptoms that result from abnormal autonomic functions, and understand how drugs affect the ANS.

## 2.0 OBJECTIVES

At the end of this unit, you will be able to:

- distinguish further between the ANS and the somatic system.
- predict the effects of sympathetic versus parasympathetic stimulation on specific organs.

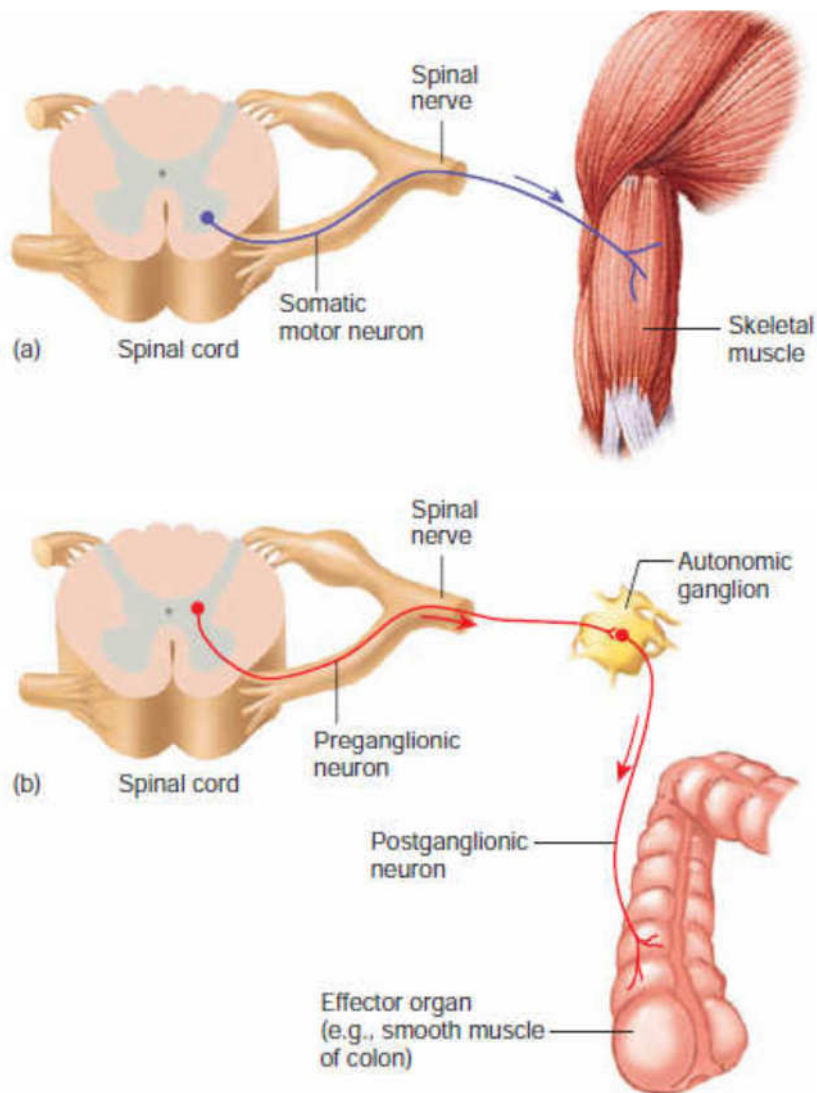
## 3.0 MAIN CONTENTS

### 3.1 Difference between PNS and ANS

The peripheral nervous system (PNS) is composed of sensory and motor neurons. Sensory neurons carry action potentials from the periphery to the central nervous system (CNS), and motor neurons carry action potentials from the CNS to the periphery. Motor neurons are either somatic motor neurons, which innervate skeletal muscle, or autonomic motor neurons, which innervate smooth muscle, cardiac muscle, and glands.

Although axons of autonomic, somatic, and sensory neurons are in the same nerves, the proportion varies from nerve to nerve. For example, nerves innervating smooth muscle, cardiac muscle, and glands, such as the vagus nerves, consist primarily of axons of autonomic motor neurons and sensory neurons. Nerves innervating skeletal muscles, such as the sciatic nerves, consist primarily of axons of somatic motor neurons and sensory neurons. Some cranial nerves, such as the olfactory, optic, and vestibulocochlear nerves, are composed entirely of axons of sensory neurons. The cell bodies of somatic motor neurons are in the CNS, and their axons extend from the CNS to skeletal muscle. The ANS, on the other hand, has two neurons in a series extending between the CNS and the organs innervated.

The first neurons of the series are called preganglionic neurons. Their cell bodies are located in the CNS within either the brainstem or the lateral part of the spinal cord gray matter, and their axons extend to autonomic ganglia located outside the CNS. The autonomic ganglia contain the cell bodies of the second neurons of the series, which are called postganglionic neurons. The preganglionic neurons synapse with the postganglionic neurons in the autonomic ganglia. The axons of the postganglionic neurons extend from autonomic ganglia to effector organs, where they synapse with their target tissues.



### 3.2 Anatomy of the ANS

The ANS is subdivided into the **sympathetic** and the **parasympathetic divisions** and the **enteric nervous system (ENS)**. The sympathetic and parasympathetic divisions differ structurally in (1) the location of their preganglionic neuron cell bodies within the CNS and (2) the location of their autonomic ganglia. The enteric nervous system is a complex network of neuron cell bodies and axons within the wall of the digestive tract. An important part of this network is sympathetic and parasympathetic neurons. For this reason, the enteric nervous system is considered to be part of the ANS.

### 3.3 Sympathetic Division

Cell bodies of sympathetic preganglionic neurons are in the lateral horns of the spinal cord gray matter between the first thoracic (T1) and the second lumbar (L2) segments. The sympathetic division is sometimes

called the **thoracolumbar division** because of the location of the preganglionic cell bodies.

The axons of preganglionic neurons are small in diameter and myelinated. The short connection between a spinal nerve and a sympathetic chain ganglion through which the preganglionic axons pass is called a white ramus communicans because of the whitish colour of the myelinated axons. Sympathetic axons exit the sympathetic chain ganglia by the following four routes:

1. *Spinal nerves* - Preganglionic axons synapse with postganglionic neurons in sympathetic chain ganglia. They can synapse at the same level that the preganglionic axons enter the sympathetic chain, or they can pass superiorly or inferiorly through one or more ganglia and synapse with postganglionic neurons in a sympathetic chain ganglion at a different level.

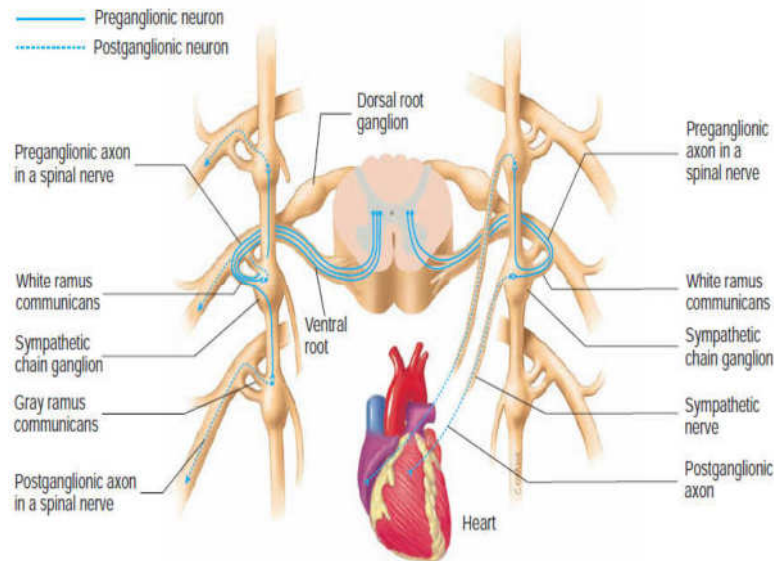
Axons of the postganglionic neurons pass through a gray ramus communicans and re - enter a spinal nerve. Postganglionic axons are not myelinated, thereby giving the gray ramus communicans its grayish colour. All spinal nerves receive postganglionic axons from a gray ramus communicans. The postganglionic axons then project through the spinal nerve to smooth muscle and glands located in the skin and skeletal muscles.

2. *Sympathetic nerves* - Preganglionic axons enter the sympathetic chain and synapse in a sympathetic chain ganglion at the same or a different level with postganglionic neurons. The postganglionic axons leaving the sympathetic chain ganglion form sympathetic nerves, which supply organs in the thoracic cavity.
3. *Splanchnic nerves*- Some preganglionic axons enter sympathetic chain ganglia and, without synapsing, exit at the same or a different level to form splanchnic nerves. Those preganglionic axons extend to collateral ganglia, where they synapse with postganglionic neurons. Axons of the postganglionic neurons leave the collateral ganglia through small nerves that extend to effector organs in the abdominopelvic cavity.
4. *Innervation to the adrenal gland* – The splanchnic nerve innervation to the adrenal glands is different from other ANS nerves because it consists of only preganglionic neurons. Axons of the preganglionic neurons do not synapse in sympathetic chain ganglia or in collateral ganglia. Instead, the axons pass through those ganglia and synapse with cells in the adrenal medulla. The adrenal medulla is the inner portion of the adrenal gland;

it consists of specialized cells derived during embryonic development from neural crest cells, which are the same population of cells that gives rise to the postganglionic cells of the ANS. Adrenal medullary cells are round, have no axons or dendrites, and are divided into two groups. About 80% of the cells secrete epinephrine also called adrenaline and about 20% secrete norepinephrine, also called noradrenaline. Stimulation of these cells by preganglionic axons causes the release of epinephrine and norepinephrine. These substances circulate in the blood and affect all tissues having receptors to which they can bind. The general response to epinephrine and norepinephrine released from the adrenal medulla is to prepare the individual for physical activity. Secretions of the adrenal medulla are considered hormones because they are released into the general circulation and travel some distance to the tissues in which they have their effect.

### 3.4 Parasympathetic Division

The cell bodies of parasympathetic preganglionic neurons are either within cranial nerve nuclei in the brainstem or within the lateral parts of the gray matter in the sacral region of the spinal cord from S2 to S4. For that reason, the parasympathetic division is sometimes called the **craniosacral division**. Axons of the parasympathetic preganglionic neurons from the brain are in **cranial nerves III, VII, IX, and X** and from the spinal cord in **pelvic splanchnic nerves**. The preganglionic axons course through these nerves to **terminal ganglia**, where they synapse with postganglionic neurons. The axons of the postganglionic neurons extend relatively short distances from the terminal ganglia to the effector organs. The terminal ganglia are either near or embedded within the walls of the organs innervated by the parasympathetic neurons. Many of the parasympathetic ganglia are small but some, such as those in the wall of the digestive tract, are large.



### 3.5 Physiology of ANS

#### Neurotransmitters

Sympathetic and parasympathetic nerve endings secrete one of two neurotransmitters. If the neuron secretes acetylcholine, it is a **cholinergic neuron**; if it secretes norepinephrine (or epinephrine), it is an **adrenergic neuron**. Adrenergic neurons are so named because at one time it was believed that they secreted adrenaline, which is another name for epinephrine. All preganglionic neurons of the sympathetic and parasympathetic divisions and all postganglionic neurons of the parasympathetic division are cholinergic. Almost all postganglionic neurons of the sympathetic division are adrenergic, but a few postganglionic neurons that innervate thermoregulatory sweat glands are cholinergic. In recent years, substances in addition to the regular neurotransmitters have been extracted from ANS neurons. These substances include nitric oxide; fatty acids, such as eicosanoids; peptides, such as gastrin, somatostatin, cholecystokinin, vasoactive intestinal peptide, enkephalins, and substance P; and monoamines, such as dopamine, serotonin, and histamine. The specific role that many of these compounds play in the regulation of the ANS is unclear, but they appear to function as either neurotransmitters or neuromodulator substances.

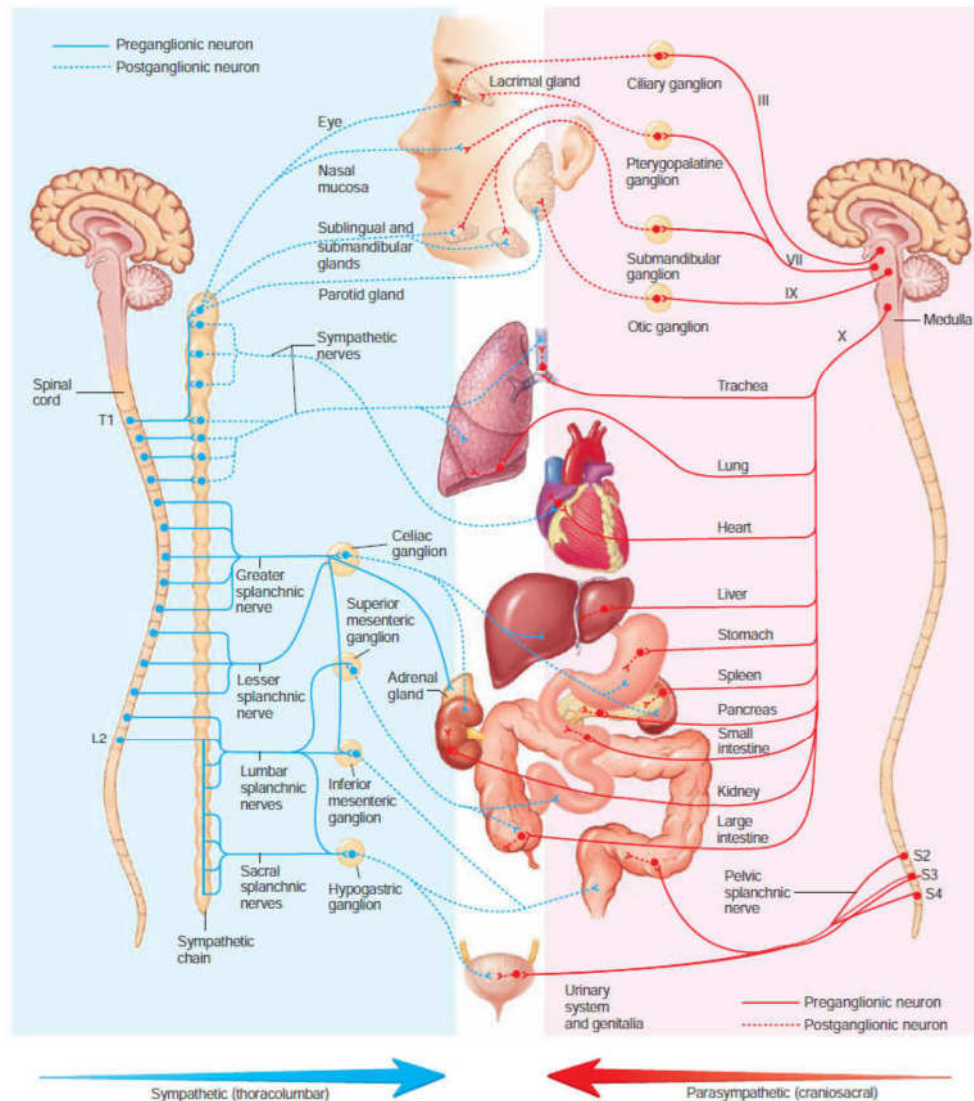
#### 3.6 Receptors

Receptors for acetylcholine and norepinephrine are located in the plasma membrane of certain cells. The combination of neurotransmitter and receptor functions as a signal to cells, causing them to respond. Depending on the type of cell, the response is excitatory or inhibitory.

## Cholinergic Receptors

**Cholinergic receptors** are receptors to which acetylcholine binds. They have two major, structurally different forms. **Nicotinic receptors** bind to nicotine, an alkaloid substance found in tobacco, and **muscarinic receptors** bind to muscarine, an alkaloid extracted from some poisonous mushrooms. Although nicotine and muscarine are not naturally in the human body, they demonstrate the differences between the two classes of cholinergic receptors. Nicotine binds to nicotinic receptors but not to muscarinic receptors, whereas muscarine binds to muscarinic receptors but not to nicotinic receptors. On the other hand, nicotinic and muscarinic receptors are very similar because acetylcholine binds to and activates both types of receptors. The membranes of all postganglionic neurons in autonomic ganglia and the membranes of skeletal muscle cells have nicotinic receptors. The membranes of effector cells that respond to acetylcholine released from postganglionic neurons have muscarinic receptors.





ANS supply to organs of the body

### 3.7 Regulation of ANS

Much of the regulation of structures by the ANS occurs through autonomic reflexes, but input from the cerebrum, the hypothalamus, and other areas of the brain allows conscious thoughts and actions, emotions, and other CNS activities to influence autonomic functions. Without the regulatory activity of the ANS, an individual has limited ability to maintain homeostasis. **Autonomic reflexes**, like other reflexes, involve sensory receptors, sensory neurons, interneurons, motor neurons, and effector cells. For example, **baroreceptors** (stretch receptors) in the walls of large arteries near the heart detect changes in blood pressure, and sensory neurons transmit information from the baroreceptors through the glossopharyngeal and vagus nerves to the medulla oblongata. Interneurons in the medulla oblongata integrate the information, and action potentials are produced in autonomic neurons that extend to the heart. If baroreceptors detect a change in blood

pressure, autonomic reflexes change heart rate, which returns blood pressure to normal.

A sudden increase in blood pressure initiates a parasympathetic reflex, which inhibits cardiac muscle cells and reduces heart rate, thus bringing blood pressure down toward its normal value. Conversely, a sudden decrease in blood pressure initiates a sympathetic reflex, which stimulates the heart to increase its rate and force of contraction, thus increasing blood pressure. Other autonomic reflexes participate in the regulation of blood pressure. For example, numerous sympathetic neurons transmit a low but relatively constant frequency of action potentials that stimulate blood vessels throughout the body, keeping them partially constricted. If the vessels constrict further, blood pressure increases; if they dilate, blood pressure decreases. Thus, altering the frequency of action potentials delivered to blood vessels along sympathetic neurons can either raise or lower blood pressure.

The brainstem and the spinal cord contain important autonomic reflex centers responsible for maintaining homeostasis. The hypothalamus, however, is in overall control of the ANS. Almost any type of autonomic response can be evoked by stimulating a part of the hypothalamus, which in turn stimulates ANS centers in the brainstem or spinal cord. Although there is overlap, stimulation of the posterior hypothalamus produces sympathetic responses, whereas stimulation of the anterior hypothalamus produces parasympathetic responses. In addition, the hypothalamus monitors and controls body temperature. The hypothalamus has connections with the cerebrum and is an important part of the limbic system, which plays an important role in emotions. The hypothalamus integrates thoughts and emotions to produce ANS responses. Pleasant thoughts of a delicious banquet initiate increased secretion by salivary glands and by glands within the stomach and increased smooth muscle contractions within the digestive system. These responses are controlled by parasympathetic neurons. Emotions such as anger increase blood pressure by increasing heart rate and constricting blood vessels through sympathetic stimulation. The enteric nervous system is involved with autonomic and local reflexes that regulate the activity of the digestive tract. For example, in an ANS reflex, sensory neurons detecting stretch of the digestive tract wall send action potentials to the CNS. In response, the CNS sends action potentials out the ANS, causing smooth muscle in the digestive tract wall to contract.

The neurons of the enteric nervous system also operate independently of the CNS to produce local reflexes. A **local reflex** does not involve the CNS, but it does produce an involuntary, unconscious, stereotypic response to a stimulus. For example, sensory neurons not connected to

the CNS detect stretch of the digestive tract wall. These sensory neurons send action potentials through the enteric plexuses to motor neurons, causing smooth muscle contraction or relaxation.

### **Clinical correlates**

#### **Effects of Spinal Cord Injury on ANS Functions**

Spinal cord injury can damage nerve tracts, resulting in the loss of sensation and motor control below the level of the injury. Spinal cord injury also interrupts the control of autonomic neurons by ANS centers in the brain. For the parasympathetic division, effector organs innervated through the sacral region of the spinal cord are affected, but most effector organs still have normal parasympathetic function because they are innervated by the vagus nerve. For the sympathetic division, brain control of sympathetic neurons is lost below the site of the injury. The higher the level of injury, the greater the number of body parts affected.

Immediately after spinal cord injury, spinal cord reflexes below the level of the injury are lost, including ANS reflexes. With time, the reflex centers in the spinal cord become functional again. This recovery is particularly important for reflexes involving urination and defecation. Autonomic reflexes mediated through the vagus nerves or the enteric nervous system are not affected by spinal cord injury.

#### **Dopamine and the Treatment of Shock**

Norepinephrine is produced from a precursor molecule called dopamine. Certain sympathetic neurons release dopamine, which binds to dopamine receptors. Dopamine is structurally similar to norepinephrine and it binds to beta receptors. Dopamine hydrochloride has been used successfully to treat circulatory shock because it can bind to dopamine receptors in kidney blood vessels. The resulting vasodilation increases blood flow to the kidneys and prevents kidney damage. At the same time, dopamine can bind to beta receptors in the heart, causing stronger contractions.

#### **Self-Assessment Exercise**

Describe the effects of sympathetic versus parasympathetic stimulation on specific organs.

#### **Activity**

In the anatomy museum, locate and examine any parts of the autonomic nervous system on models available.

#### **4.0 CONCLUSION**

The cell bodies of somatic motor neurons are located in the CNS, and their axons extend to skeletal muscles, where they have an excitatory effect that usually is controlled consciously.

#### **5.0 SUMMARY**

- The cell bodies of the preganglionic neurons of the ANS are located in the CNS and extend to ganglia, where they synapse with postganglionic neurons. The postganglionic axons extend to smooth muscle, cardiac muscle, or glands and have an excitatory or inhibitory effect, which usually is controlled unconsciously.
- Preganglionic cell bodies are in the lateral horns of the spinal cord gray matter from T1 to L2. Preganglionic axons pass through the ventral roots to the white rami communicantes to the sympathetic chain ganglia.
- Preganglionic cell bodies are in nuclei in the brainstem or the lateral parts of the spinal cord gray matter from S2 to S4. Preganglionic axons from the brain pass to ganglia through cranial nerves. Preganglionic axons from the sacral region pass through the pelvic splanchnic nerves to the ganglia. Preganglionic axons pass to terminal ganglia within the wall of or near the organ that is innervated.
- Sympathetic, parasympathetic, and sensory neurons intermingle in autonomic nerve plexuses. Sympathetic axons reach organs through spinal, sympathetic, and splanchnic nerves.
- Parasympathetic axons reach organs through cranial and pelvic splanchnic nerves. Sensory neurons run alongside sympathetic and parasympathetic neurons within nerves and nerve plexuses.
- Acetylcholine is released by cholinergic neurons (all preganglionic neurons, all parasympathetic postganglionic neurons, and some sympathetic postganglionic neurons).
- Norepinephrine is released by adrenergic neurons (most sympathetic postganglionic neurons). Acetylcholine binds to nicotinic receptors (found in all postganglionic neurons) and muscarinic receptors (found in all parasympathetic and some sympathetic effector organs). Norepinephrine and epinephrine bind to alpha and beta receptors (found in most sympathetic effector organs).

- Activation of nicotinic receptors is excitatory, whereas activation of muscarinic, alpha, and beta receptors is either excitatory or inhibitory.

## 6.0 TUTOR MARKED ASSIGNMENT

1. Given these phrases:

1. Neuron cell bodies in the nuclei of cranial nerves
2. Neuron cell bodies in the lateral gray matter of the spinal cord (S2–S4)
3. Two synapses between the CNS and effector organs
4. Regulates smooth muscle

Which of the phrases are true for the autonomic nervous system?

- a. 1,3
- b. 2,4
- c. 1,2,3
- d. 2,3,4
- e. 1,2,3,4

2. Given these structures:

1. gray ramus communicans
2. white ramus communicans
3. sympathetic chain ganglion

Choose the arrangement that lists the structures in the order an action potential passes through them from a spinal nerve to an effector organ.

- a. 1,2,3
- b. 1,3,2
- c. 2,1,3
- d. 2,3,1
- e. 3,2,1

3. Given these structures:

1. collateral ganglion
2. sympathetic chain ganglion
3. white ramus communicans
4. splanchnic nerve

Choose the arrangement that lists the structures in the order an action potential travels through them on the way from a spinal nerve to an effector organ.

- a. 1,3,2,4
  - b. 1,4,2,3
  - c. 3,1,4,2
  - d. 3,2,4,1
  - e. 4,3,1,2
4. The white ramus communicans contains
- a. preganglionic sympathetic fibers.
  - b. postganglionic sympathetic fibers.
  - c. preganglionic parasympathetic fibers.
  - d. postganglionic parasympathetic fibers.
5. The cell bodies of the postganglionic neurons of the sympathetic division are located in the
- a. sympathetic chain ganglia
  - b. collateral ganglia.
  - c. terminal ganglia.
  - d. dorsal root ganglia.
  - e. both a and b.
6. Splanchnic nerves
- a. are part of the parasympathetic division.
  - b. have preganglionic neurons that synapse in the collateral ganglia.
  - c. exit from the cervical region of the spinal cord.
  - d. travel from the spinal cord to the sympathetic chain ganglia.
  - e. all of the above.
7. Which of the following statements regarding the adrenal gland is true?
- a. The parasympathetic division stimulates the adrenal gland to release acetylcholine.
  - b. The parasympathetic division stimulates the adrenal gland to release epinephrine.
  - c. The sympathetic division stimulates the adrenal gland to release acetylcholine.
  - d. The sympathetic division stimulates the adrenal gland to release epinephrine.
8. The parasympathetic division
- a. is also called the craniosacral division.
  - b. has preganglionic axons in cranial nerves.

- c. has preganglionic axons in pelvic splanchnic nerves.
  - d. has ganglia near or in the wall of effector organs.
  - e. all of the above.
9. Which of these is *not* a part of the enteric nervous system?
- a. ANS motor neurons
  - b. neurons located only in the digestive tract
  - c. sensory neurons
  - d. somatic motor neurons
10. Concerning the distribution of autonomic axons,
- a. autonomic nerve plexuses contain sympathetic and parasympathetic axons.
  - b. sympathetic axons reach the skin and skeletal muscles of most of the body through spinal nerves.
  - c. sympathetic axons reach thoracic organs and parts of the head and neck through sympathetic nerves.
  - d. sympathetic axons reach abdominopelvic organs through splanchnic nerves.
  - e. all of the above.

## 7.0 REFERENCES AND OTHER RESOURCES

- Hutchinson, M., Mallat, J., Marieb, E.N., Wilhelm P.B. (2007). A Brief Atlas of the Human Body. San Francisco: Pearson Education Inc.
- Katherine M. A. Rogers and William N. Scott (2011) Nurses! Test Yourself in Anatomy and Physiology
- Kathryn A. Booth, Terri. D. Wyman (2008) Anatomy, Physiology, and Pathophysiology for Allied Health
- Keith L Moore, Persuade T.V.N (2018), The Developing Human Clinically Oriented Embryology 11th Edition Lippincott Williams & Wilkins
- Kent M. Van De Graff, R.Ward Rhee, Sidney Palmer (2010) Schaum's Outline of human Anatomy and Physiology 3rd edition.
- Philip Tate (2012) Seeley's Principles of Anatomy & Physiology 2nd ed.

Sadler T.W (2012), Langman's Medical Embryology 12th edition.  
Seeley's Principles of Anatomy & Physiology, Second edition Published  
by McGraw-Hill, a business unit of The McGraw-Hill  
Companies, Inc., 1221 Avenue of the Americas, New York, NY  
10020. Copyright c 2012- Chapter 17&18